

CASE STUDIES SYNEO

A Global collection of Clinical Case Studies on the dietary management of cow's milk allergy with **Pepti Syneo** and **Neocate Syneo**



For healthcare professionals only.

Pepti Syneo and Neocate Syneo are Foods for Special Medical Purposes for use under medical supervision.

Accurate at time of publication, January 2022.

NUTRICIA
LIFE-TRANSFORMING NUTRITION

INTRODUCTION

The gut is the centre of the immune system and early life nutrition is a key factor for the development of a healthy gut microbiota and immunity. The role of the microbiome in the development of allergic diseases has been described extensively. While the gut microbiome of breastfed infants shows a predominant bifidogenic profile, several studies show an imbalance of the gut microbiota of infants with cow's milk allergy (CMA).

Synbiotics are the latest addition to our range of hypoallergenic formula for infants with CMA: Pepti Syneo (extensively hydrolysed formula, eHF) and Neocate Syneo (amino acid-based formula, AAF). **Syneo, a patented blend of synbiotics, contains our unique mix of prebiotics and probiotics that work together synergistically to support the gut microbiota and developing immune system. This is backed by 10 years of research, including studies involving over 1,500 infants.**

Clinical studies show that our hypoallergenic formulas with synbiotics support healthy growth and positively influence the gut microbiota of infants with CMA bringing it closer to that of healthy breastfed infants, to support the developing immune system¹⁻⁴. Interestingly, additional outcomes show fewer reports of antibiotic use, infections, and hospitalizations due to infections in infants using an AAF with synbiotics*. These preliminary findings are clinically relevant in this group of infants who may be more susceptible to infections.

This case study booklet contains a range of seventeen case studies written by healthcare professionals from different countries. The objective of this booklet is to provide you with real-life, practical insights on the diagnosis and management of infants with CMA. It describes clinical practices of CMA management around the world and the use of Pepti Syneo & Neocate Syneo, to complement the extensive evidence available on synbiotics from clinical studies.

Each case illustrates different challenges, e.g. history of prematurity, formula acceptance issues, faltering growth, multiple food allergies, experiencing gastrointestinal (GI), dermatological, respiratory symptoms, and describes the impact of CMA on infants and their families.

Nutricia would like to thank all the healthcare professionals for sharing their case studies and for their contributions to this booklet.

This case study booklet is intended for Healthcare Professionals only.

¹ Burks A et al. *Pediatr Allergy Immunol.* 2015;26(4):316-22..

² Candy D et al. *Pediatr Res.* 2018;83(3):677-86.

³ Fox AT et al. *Clin Transl Allergy.* 2019;9:5.

⁴ Chatchatee P et al. *JACI.* 2021

* Based on evaluation of adverse events

CASE STUDIES OVERVIEW

PEPTI SYNEO

Case study	Short case description	Healthcare professional, profession	Country
Baby A	Infant with atopic dermatitis and feeding difficulties	Beata Cudowska Paediatrician/ Allergologist	Poland
Baby B	Infant with Down's syndrome with many hospital visits due to CMA and respiratory symptoms	Miroslava Petrášová Paediatric Gastroenterologist	Slovakia
Baby C	Infant with bloody stools after switch to infant formula	Alfred Tam Paediatrician	Hong Kong
Baby D	Infant with chronic FPIES	Ángela Claver Monzón Paediatrician	Spain
Baby E	Mixed fed infant with mild symptoms of reflux, intermittent vomiting and eczema	Lisa Cooke Specialist Paediatric Dietitian	United Kingdom
Baby F	Infant with severe, immediate allergic reactions	Diego Peroni Paediatrician	Italy
Baby G	Challenges with an elimination diet in a breastfed infant	José Francisco Cadena León Paediatric Gastroenterologist	Mexico
Baby H	Mixed fed infant with MFA and severe atopic dermatitis	María Eugenia Gervasoni Paediatrician/Allergy Immunologist	Argentina
Baby I	Infant with persistent constipation on an eHF without synbiotics	Catherine Casewell Specialist Paediatric Dietitian	United Kingdom

NEOCATE SYNEO

Case study	Short case description	Healthcare professional, profession	Country
Baby J	Infant with severe atopic dermatitis, MFA, growth failure and loose stools	Raquel Durban Registered Dietitian	United States of America
Baby K	Infant with persistent diarrhea and blood in stool on an eHF	Mónica del Compare Paediatric Gastroenterologist	Argentina
Baby L & M	Twins born prematurely with skin and GI symptoms and faltering growth	Juan Pablo Riveros López Paediatric Gastroenterologist	Colombia
Baby N	Infant with persistent skin symptoms on an eHF	Najwa Alsawi Allergist/Immunologist	Saudi Arabia
Baby O	Infant with persistent vomiting, MFA, and FPIES	Alicia D. Tenn Paediatric Nurse Practitioner	United States of America
Baby P	Infant born prematurely with faltering growth and food refusal	Gemma Castillejo Paediatric Gastroenterologist	Spain
Baby Q	Infant with multiple GI and dermatological symptoms and long periods of crying	Dominik Fürsich Paediatrician	Germany
Baby R	Infant with eczema, vomiting and constipation	Simona Bělohávková Allergist/Immunologist	Czech Republic

SYNEO PRODUCT OVERVIEW

Our optimum range for the dietary management of cow's milk allergy (CMA) in mixed-fed or non-breastfed infants

SYNEO™ is supported by an extensive clinical study programme




DIAGNOSED WITH MILD TO MODERATE CMA Extensively Hydrolysed Formula (eHF)

APTAMIL PEPTI SYNEO

Going beyond symptom relief by targeting the gut microbiota

- Improved constipation and atopic dermatitis symptom relief¹
- Long-term impact on allergy. Significant reduction in asthma-like symptoms and asthma medication²
- Modulates the gut microbiota by increasing Bifidobacteria levels and improving metabolic profile¹ closer to that of a healthy breastfed infant




DIAGNOSED WITH SEVERE OR COMPLEX CMA/MULTIPLE FOOD ALLERGIES (MFA) Amino Acid Formula (AAF)

NEOCATE SYNEO™

Helps rebalance the gut microbiota³⁻⁵ to support immune development and long-term health⁶⁻⁹

- Effective symptom resolution and proven hypoallergenicity^{3,10}
- Fewer reports of infections, antibiotic use and infections requiring hospitalizations across clinical trials^{3-5,11}
- Balances the gut microbiota³⁻⁵ to support immune development and long-term health⁵⁻⁹



¹ Van Der Aa LB, et al. Clin Exp Allergy. 2010;(40) 795–804.

² Van Der Aa LB, et al. Allergy 2011; 66(2): 170–177

³ Burks AW et al. Pediatr Allergy Immunol. 2015;26(4):316-22.

⁴ Candy DCA et al. Pediatr Res. 2018;83(3):677-86.

⁵ Fox AT et al. Clin Transl Allergy. 2019;9:5.

⁶ Martin R, et al. Benef Microbes. 2010;1(4):367-382.

⁷ Wopereis H, et al. Pediatr Allergy Immunol. 2014;25(5):428-438.

⁸ West CE, et al. J Allergy Clin Immunol. 2015;135(1):3-13.

⁹ Walker WA, et al. Pediatr Res. 2015;77(1):220-228.

¹⁰ Harvey BM, et al. Pediatr Res. 2014;75(2):343-351.

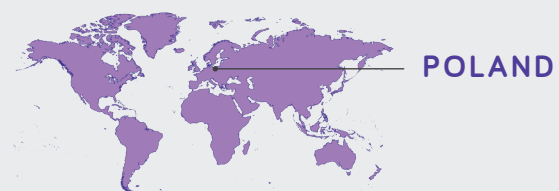
¹¹ Chatchatee P, et al. Allergy Clin Immunol. 2021;S0091-6749(21)01053-8.



INFANT WITH ATOPIC DERMATITIS AND FEEDING DIFFICULTIES

BABY A

Beata Cudowska Paediatrician/Allergologist
Medical University of Bialystok.



PATIENT PROFILE

Breastfed infant with IgE-mediated cow's milk allergy (CMA), born by caesarean section, saw a significant improvement in her atopic dermatitis and was able to stop steroid cream, as well as having a rapid resolution of her gastrointestinal symptoms, following a switch to Pepti Syneo.

- IgE-mediated CMA
- Egg allergy
- Born by caesarean section
- Family history of dust mite allergy
- Symptomatic on breastmilk (mother following elimination diet)
- Dermatological symptoms
- Gastrointestinal symptoms
- Feeding difficulties

BACKGROUND

Baby A was born at full term by caesarean section, weighing 2.7kg, and was breastfed from birth. Baby A's mother has an allergy to dust mites. At two months old baby A presented with itchy skin lesions and was diagnosed with seborrheic dermatitis. Her most severe skin lesions were on her cheeks and forehead and she presented with single erythematous papules on her torso. At three months old, she developed loose, mucus containing stools five to six times a day.

Her skin lesions worsened at three months, especially on the cheeks and torso, and she presented with dry and itchy skin all over. At four months, baby A was diagnosed with moderate atopic dermatitis. At six months old baby A presented with feeding difficulties; she refused solid foods and breastfed frequently and irregularly. Baby A was referred onto the allergy department at nine months, due to her symptoms and their lack of improvement with dietary and pharmacological interventions.

MANAGEMENT

At two months old, baby A's skin lesions were treated with topical emollients and creams containing hydrocortisone, antibiotics and antifungals. These pharmacological interventions resulted in partial and temporary improvement to her skin. It was suspected that baby A had CMA. Her mother was advised to eliminate milk from her diet, however this elimination diet was discontinued after two weeks, as there was no improvement in baby A's symptoms.

At three months, following the worsening of baby A's skin lesions, emollients and a combination of topical steroids and antibiotics were used. Baby A continued to be breastfed and her mother re-started

her milk-free diet, as well as excluding eggs, nuts and corn. At four months, baby A had the presence of specific IgE antibodies to milk (0.24 kU/L) and her mother was recommended to continue breastfeeding while following a milk-free diet. Complementary feeding, with meat, fruit and vegetables was initiated at six months, and the exacerbation of baby A's skin lesions continued. Baby A was examined twice by allergy doctors, at six and seven months, due to her exacerbated skin lesions.

At nine months, after being referred to the allergy department, baby A scored 45 on the SCORAD (SCORing Atopic Dermatitis) tool, and her diagnosis

MANAGEMENT (CONT.)

of atopic dermatitis was confirmed¹. Baby A had multiple allergy tests: Her total IgE level was high (374 kU/L), and she had positive specific IgE antibodies to

milk (1.4 kU/L), beta-lactoglobulin (0.45 kU/L) and chicken egg white (8.3 kU/L). Baby A also tested positive for methicillin-resistant *Staphylococcus aureus* (MRSA).

FOLLOW UP CARE

At nine months, baby A's mother was advised to continue eliminate milk, chickens eggs and corn from her diet and reduce breastfeeding to three times a day. To regulate baby A's milk intake and ensure she had an adequate protein and calorie intake, the addition of 180ml of **Pepti Syneo** one to two times per day was recommended. **Pepti Syneo** was decided on for multiple reasons including the atopic dermatitis symptoms and baby A's risk factors for a disrupted gut microbiota; MRSA and being born by cesarean section.

Given baby A's feeding difficulties and her mothers' reluctance to continue on a strict elimination diet, breastfeeding was discontinued. 180ml of **Pepti Syneo** was commenced three to four times a day alongside meals and grain products. After four days, baby A began to pass normal stools without mucus and after a week her appetite had improved. After two weeks, the severity of her skin lesions significantly reduced; her SCORAD score fell to 15, indicating mild atopic dermatitis. Baby A continued to use topical emollients, but was able to stop her steroid cream. Any exacerbations in her skin condition were usually triggered by environmental factors such as temperature.

At her follow up appointment, at ten months old, baby A was taking 500ml of **Pepti Syneo** per day and tolerating it well. She now willingly ate her meals and was growing normally. At 15 months old an oral food challenge to baked milk, under clinical supervision, indicated good tolerance of heat treated cow's milk proteins. At this point, **Pepti Syneo** was reduced to 200-300ml/day.

At 18 months, Baby A had a follow up visit and showed a reduction in her specific IgE antibody levels to milk. At two years old, baby A has stopped **Pepti Syneo** and receives products containing cow's milk. She continued to be allergic to eggs and excluded these from the diet.

“
After four days, baby A began to pass normal stools without mucus and after a week her appetite had improved. After two weeks, the severity of her skin lesions significantly reduced. She now willingly ate her meals and was growing normally.”

DISCUSSION

The disruption of the gut microbiota is an important factor in the development of allergic diseases and is shown by a decrease in *Bifidobacterium* spp. and an increase in *Clostridium*.

Feeding with extensively hydrolysed formula (eHF)

with synbiotics should be considered in CMA infants with risk factors for gut microbiota disorders. In children with atopic dermatitis and IgE-mediated food allergy, especially those up to the age of two years, randomised control trials have shown that using eHF with synbiotics benefits the gut microbiota and reduces atopic dermatitis symptoms^{2,3}.

CONCLUSION

In this infant with IgE-mediated CMA, the introduction of Pepti Syneo had a positive effect on her dermatological and gastrointestinal symptoms, with her SCORAD score decreasing and her stools ceasing to be loose and mucus containing. Commencing Pepti Syneo was also an important factor for facilitating the development of baby A's food tolerance.

¹ Oranje A. Practical issues on interpretation of scoring atopic dermatitis: SCORAD Index, objective SCORAD, patient-oriented SCORAD and Three-Item Severity score. *Current problems in dermatology*. 2011; 41:149-155.

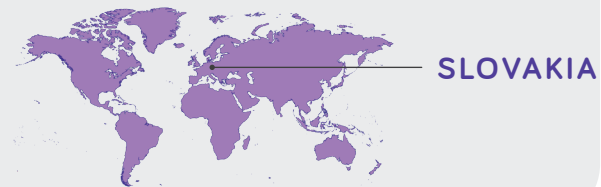
² Van Der Aa LB, et al. *Clin Exp Allergy*. 2010;(40):795-804.

³ Van Der Aa LB, et al. *Allergy*. 2011;66(2):170-177.

INFANT WITH DOWN'S SYNDROME WITH MANY HOSPITAL VISITS DUE TO CMA AND RESPIRATORY SYMPTOMS

BABY B

Miroslava Petrášová Paediatric Gastroenterologist
Children's University Hospital Košice



PATIENT PROFILE

Infant with Down's syndrome and non-IgE mediated cow's milk allergy, who switched from a standard infant formula to Pepti Syneo, saw a fast resolution of gastrointestinal (GI), respiratory and dermatologic symptoms.

- Non-IgE mediated CMA
- Gastrointestinal symptoms
- Dermatologic symptoms
- Respiratory symptoms
- Infant antibiotic use
- Family history of asthma and CMA

BACKGROUND

Baby B is an infant with Down's syndrome who has a family history of asthma and cow's milk allergy (CMA). As an infant, baby B was prescribed antibiotics and exposed to household smoking. At birth, he was commenced on a standard infant formula. Baby B had GI symptoms of colic and bloating. At three months, he developed wheezing and atopic dermatitis on his face, which subsequently spread. Between

age three and five months, baby B had several visits to the emergency room. At five months and two weeks old, baby B's clinical condition worsened, and he developed dehydration and dyspnoea (shortness of breath). He was admitted to hospital following an episode of wheezing, diarrhoea, and dermatitis (predominantly on his face and lower extremities) and was found to have a *Clostridium difficile* infection.

MANAGEMENT

Between three and five months baby B had several visits to the emergency department, without hospital admission, where his wheezing was treated with a combination of bronchodilators, oral and inhaled steroids and/or antibiotics.

Baby B was admitted to hospital at five months and two weeks old, following a worsening of his clinical condition. He was treated with a course of metronidazole, intravenous fluid replacement, inhaled steroids and a combination of bronchodilators. This worsening in baby B's clinical condition was a result of his parents not following the advice given at his out-

patient appointments. Baby B's parents' low socio-economic status also had an impact; bronchodilators, antihistamines and other symptomatic agents were only partially or not covered at all by baby B's insurance and therefore were not administered to him.

Baby B scored a 44.3 using the SCORAD (SCORing Atopic Dermatitis) tool¹ and had a negative serum-specific IgE test. A diagnosis of CMA was suspected, and baby B was recommended to switch from his standard infant formula to Pepti Syneo, an extensively hydrolysed formula (eHF) with synbiotics.

¹ Oranje A. Practical issues on interpretation of scoring atopic dermatitis: SCORAD Index, objective SCORAD, patient-oriented SCORAD and Three-Item Severity score. *Current problems in dermatology*. 2011; 41:149-155.

FOLLOW UP CARE

Baby B commenced **Pepti Syneo** at five months and two weeks old. He tolerated it well, without any transition period, and it was effective in bringing relief to his allergy symptoms. Within a week, his diarrhoea had ceased and the frequency of his wheezing episodes were significantly reduced. In three weeks, his skin normalised, with his mother reporting decreased redness, dryness and scratching from baby B, and a resultant improvement in his sleep. His reduction in wheezing episodes also led to a decreased rate of hospitalization. Baby B's stools also normalised after the introduction of **Pepti Syneo**. Baby B's diagnosis of CMA was based on the cessation of his symptoms.

Complementary feeding on a strict cow's milk elimination diet was introduced at five months and three weeks old. This introduction occurred during baby B's hospital admission, after his GI symptoms had resolved. However, when baby B was ten months old, against recommendation, his family reintroduced foods with cow's milk protein. Baby B's atopic dermatitis returned, although he didn't have any GI or respiratory symptoms.

At his mothers' request, a provocation test was performed after 4 months (before the recommended six months) following his elimination diet to assess tolerance and he hadn't yet developed tolerance.

“
He tolerated [Pepti Syneo] well, without any transition period, and it was effective in bringing relief to his allergy symptoms.”

DISCUSSION

CMA is closely associated with other atopic symptoms. Expert guidelines recommend an eHF or an amino acid formula for children with severe symptoms of CMA, with reevaluation every six to twelve months, to assess the child's development of tolerance to cow's milk protein. An early diagnosis of CMA is key in achieving a positive outcome and control symptoms.

“
A reduction in his wheezing episodes also led to a decreased need for hospitalizations.”

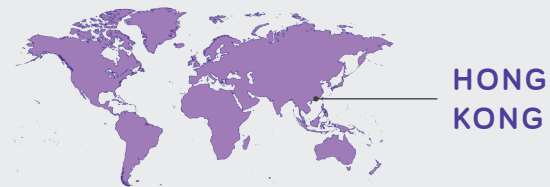
CONCLUSION

In this non-breastfed infant, a switch from a standard infant formula to Pepti Syneo resulted in a significant improvement in GI, respiratory and dermatologic allergic symptoms. A reduction in his wheezing episodes also led to a decreased need for hospitalizations. The combination of eHF and synbiotics in Pepti Syneo were effective in the dietary management of CMA.

INFANT WITH BLOODY STOOLS AFTER SWITCH TO INFANT FORMULA

BABY C

Alfred Tam Paediatrician
University of Hong Kong and the Chinese University
of Hong Kong



HONG
KONG

PATIENT PROFILE

Cow's milk formula fed infant, born by caesarean section, with IgE-mediated cow's milk allergy (CMA), saw a quick resolution of bloody stools after switching to Pepti Syneo.

- IgE-mediated CMA
- Born by caesarean section
- Gastrointestinal symptoms
- Dermatologic symptoms
- Family history of eczema

BACKGROUND

Baby C was born at full term (38 weeks) by elective caesarean section, weighing 2.88kg. He has a seven year old sister, who has had eczema since infancy and had recurrent wheezing between ages one to three years. Baby C was well at birth and was breastfed along with supplementary cow's milk formula for the first month of life, before switching to cow's milk formula as the sole source of nutrition. A

week after his mother stopped breastfeeding, baby C was passing three to four loose stools a day, with one to two being stained with a small amount of fresh blood. Baby C had mild seborrheic dermatitis, a soft and non-tender abdomen with mild gaseous distension. However, he was feeding well, managing 800ml of feed without vomiting, and growing within normal parameters.

MANAGEMENT

Baby C's fresh blood stained stool was tested and the culture was negative. It was suspected that baby C had IgE-mediated CMA. His cow's milk formula was switched to Pepti Syneo, and the blood in his stools quickly ceased. After two weeks of Pepti Syneo, baby C's mother re-introduced cow's milk formula and several days later the blood reappeared in baby C's stools. This reaction formed the basis for baby C's cow's milk allergy diagnosis, and affected his treatment going forward. His allergy was suspected to be IgE-mediated given his eczema and atopic family history.

Baby C's eczema started to develop at two and a half months, mainly affecting his cheeks, elbow folds, abdomen and both legs. With the exception of occasional weather related flare ups, his eczema was effectively controlled with an intermittent topical steroid and continuous skin protection from oil and moisturisers.

“
Cow's milk formula was switched to Pepti Syneo, and the blood in his stools quickly ceased.”

FOLLOW UP CARE

After baby C's CMA diagnosis, he was fed exclusively with **Pepti Syneo**. He tolerated this feed well and at six months he was having up to 900ml of feed per day. Complementary feeding was introduced at five months. Baby C didn't show symptoms of an allergic reaction to any foods including dairy, which was introduced around nine months old. As recommended by most guidelines, baby C continued with **Pepti Syneo** until one year old. He was then switched to cow's milk.

Baby C grew out of his CMA. At two years, baby C could tolerate all foods, including dairy products and, with the exception of a small rough patch on his legs, there were no issues with his skin. Baby C's growth remained satisfactory throughout.

“
At two years, baby C could tolerate all foods, including dairy products”

DISCUSSION

CMA is the most common cause of fresh blood stained stool in early infancy. Often this is due to an IgE-mediated allergy. There is a non-IgE mediated mechanism causing CMA, but this is not completely understood, especially when only the gastrointestinal tract is involved.

Most guidelines recommend the use of specific IgE antibodies to cow's milk to diagnose IgE-mediated CMA. However, when a blood test is not possible, cow's milk protein withdrawal and challenge can be used as an alternative method of diagnosis. However, milk challenge remains the only standard test for non-IgE mediated CMA.

Baby C managed his CMA symptoms after switching to Pepti Syneo. The role of pre- and probiotics has been extensively studied in food allergies and it is known that the gut microbiota plays an important role in prevention and tolerance development.

Baby C's eczema continued after he was able to tolerate cow's milk, suggesting that the eczema was present independent of the cow's milk allergy. However, one can become sensitized to an allergen via different routes including the skin, the gut and the airways. House dust mite could have been another sensitizing allergen. Baby C's continued eczema was mild, and responded to treatment from oils, moisturisers and steroids; the constant use of skin protection by moisturisers would have contributed towards decreasing sensitization via the skin.

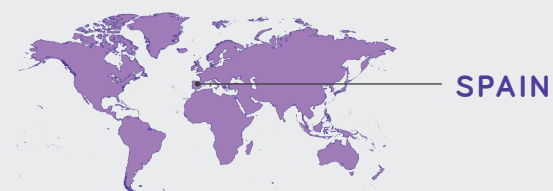
CONCLUSION

This cow's milk allergic infant had a quick and complete resolution of his bloody stools following a switch from cow's milk formula to Pepti Syneo. Baby C tolerated Pepti Syneo well, had normal growth and development and later grew out of his CMA.

INFANT WITH CHRONIC FPIES

BABY D

Ángela Claver Monzón Paediatrician
University Hospital Dexeus



SPAIN

PATIENT PROFILE

Use of Pepti Syneo in this mixed fed infant with chronic food protein-induced enterocolitis syndrome (FPIES) and non-IgE mediated cow's milk allergy (CMA) was well tolerated because of its palatability and led to fast symptom resolution.

- Non-IgE mediated CMA
- Chronic FPIES
- Faltering growth
- Feeding difficulties
- Gastrointestinal symptoms
- Symptomatic on lactose free formula

BACKGROUND

Baby D had an unremarkable medical history with no family history of allergies. He was exclusively breastfed for the first two months. When mixed feeding was commenced with a standard infant formula, baby D presented with intermittent vomiting, reflux, loose stools with mucus, bloating, inconsolable

crying, fussy eating, decreased oral intake and weight loss. Baby D's laboratory test results were normal, with negative cow's milk specific IgE levels and a negative skin prick test. A diagnosis of chronic FPIES was confirmed after baby D had an acute reaction after six days of milk protein avoidance.

MANAGEMENT

Baby D was first prescribed an anti-regurgitation formula followed by a lactose free formula, neither of which improved his symptoms (see timeline on next page). Baby D was then started on a casein extensively hydrolysed formula (eHF) without lactose, and his symptoms improved. However, baby D refused this formula and continued to lose weight. Six days after starting the casein eHF, baby D presented at the emergency room with profuse emesis, lethargy and pallor. On the day of the acute reaction, Mum had mixed one cup of standard infant formula with the casein hydrolysed formula, to improve palatability. Baby D was switched to a whey hydrolysate, Pepti, because of the improved palatability of a whey hydrolysate with lactose, and unlike the casein eHF

without lactose, he didn't refuse this formula. Pepti was tolerated perfectly and within three days, his symptoms resolved. Baby D's growth improved when he transitioned onto the whey eHF formula.

“
Pepti was tolerated perfectly and within three days, his symptoms resolved

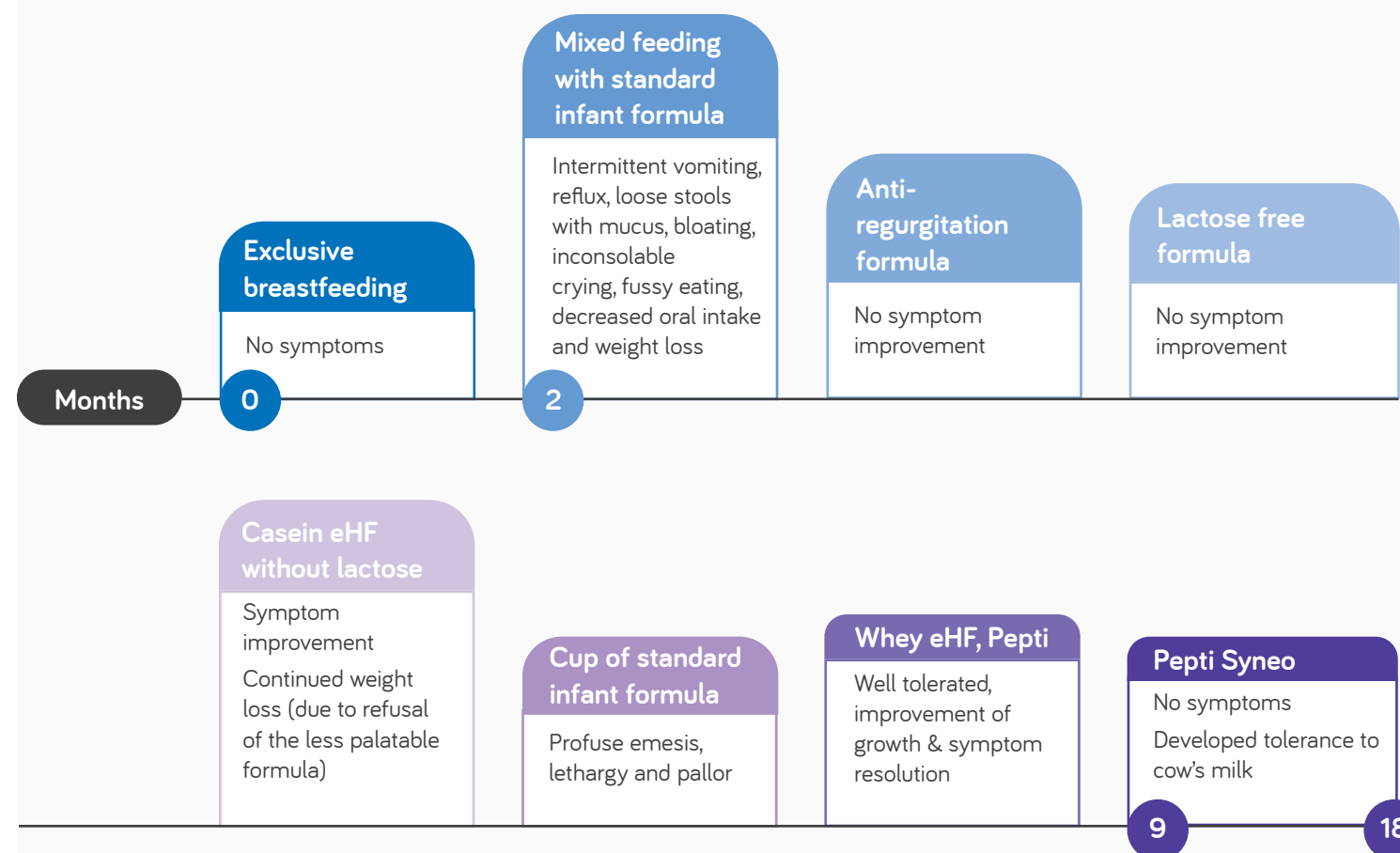
FOLLOW UP CARE

The aim of nutritional intervention was resolution of baby D's symptoms. At nine months of age, when the formula became available in Spain, baby D was switched from Pepti to **Pepti Syneo**, an eHF with synbiotics, with no tolerance issues.

Complementary foods were introduced into baby D's diet at six months. At 18 months, baby D passed a controlled oral food challenge and tolerance to cow's milk protein was acquired.

The multiple formula switches without symptom improvement caused baby D's parents to be anxious and desperate, however this improved when he switched to and tolerated well Pepti. Mum couldn't believe that baby D was eating without symptoms.

TIMELINE



Case study continues on the next page.

DISCUSSION

The diagnosis of chronic FPIES is often delayed because of its non-specific nature and delayed onset of symptoms after food ingestion. When symptoms of chronic FPIES are recognized early, elimination of the offending protein can prevent full expression of FPIES and its potential complications. Baby D refused casein eHF, so it was important to find an option with better palatability. Pepti was palatable and perfectly tolerated, with a complete improvement in symptoms in just three days. At nine months old, it was changed to Pepti Syneo, also with perfect tolerance.

“

Pepti Syneo brought symptom relief from intermittent vomiting, crying and loose stools with mucus. Baby D's growth improved, and baby D's parents became less anxious knowing that their child was able to tolerate feeds without symptoms.

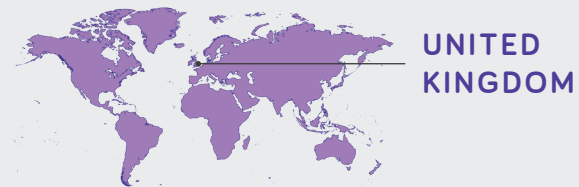
CONCLUSION

FPIES is frequently misdiagnosed, and patients undergo extensive diagnostic evaluations and multiple formula changes with no results. This mixed fed infant with chronic FPIES previously had multiple formula changes without success in managing the condition. Switching to Pepti and subsequently Pepti Syneo brought symptom relief from intermittent vomiting, crying and loose stools with mucus. Baby D's growth improved, and baby D's parents became less anxious knowing that their child was able to tolerate feeds without symptoms.

MIXED FED INFANT WITH MILD SYMPTOMS OF REFLUX, INTERMITTENT VOMITING AND ECZEMA

BABY E

Lisa Cooke Head of Paediatric Dietetics, Nutrition and SALT



PATIENT PROFILE

Non-IgE mediated cow's milk allergic infant, with an atopic family history, switched from an extensively hydrolysed formula (eHF) to Pepti Syneo and saw an improvement in his eczema after just four weeks.

- Non-IgE mediated CMA
- Family history of IgE-mediated CMA
- Gastrointestinal symptoms
- Dermatological symptoms

BACKGROUND

Baby E was born by vaginal delivery with no complications. He has a family history of IgE-mediated cow's milk allergy (CMA), with his older sibling being diagnosed with CMA. Baby E was

breastfed from birth and presented with symptoms of reflux, intermittent vomiting and eczema at an early age. It was suspected that baby E had non-IgE mediated CMA.

MANAGEMENT

At six weeks old, in an effort to alleviate baby E's gastrointestinal and dermatological symptoms, he was commenced on ranitidine and his mother began to follow a cow's milk elimination diet. Together, these management strategies were effective in relieving his symptoms. When baby E's mother trialled re-introducing cow's milk containing foods back into her diet, baby E's symptoms returned which confirmed his non-IgE mediated CMA diagnosis.

At 14 weeks old, following his diagnosis, he was referred on for specialist allergy assessment and management. Baby E's mother was keen to supplement breastfeeding with a hypoallergenic formula so he was commenced on an eHF, Pepti; baby E's symptoms remained under control. Complementary feeding, excluding cow's milk containing foods, was successfully introduced at six months old.

FOLLOW UP CARE

The aim of baby E's follow up care was to ensure that he had no relapse of his CMA symptoms, to promote a balanced gut microbiome and when appropriate, to trial the reintroduction of cow's milk.

Baby E's mother had read about probiotics and was keen for him to trial an eHF with synbiotics to support his gut microbiome. At nine and a half months old, baby E was switched from an eHF to an eHF with synbiotics, **Pepti Syneo**, which he tolerated well. His infant formula continued to supplement breastfeeding and his mother continued to follow a cow's milk elimination diet. Baby E's gastrointestinal and dermatological symptoms remained well controlled, with the exception of his eczema flaring up when he had a cold. He continued on ranitidine to manage his reflux.

Four weeks after commencing **Pepti Syneo**, baby E's POSCORAD¹ (patient-oriented score of atopic dermatitis) fell from 14.9 to 9.4. Although his symptoms were already stable on the eHF, his mother reported that he responded better after switching to **Pepti Syneo**. Baby E continued on **Pepti Syneo** for a further four months before transitioning onto oat milk at 14.5 months. At 13 months old, baby E started introducing milk using the milk ladder guide; cow's milk foods have now been successfully introduced.

Baby E had normal growth throughout, with his weight and length falling between the 91st and 98th centiles.

DISCUSSION

After managing her other child with CMA, baby E's mother had a good awareness of CMA management and the importance of a balanced gut microbiome. She proactively approached a dietitian whilst still pregnant with baby E to ensure that she was ready should her unborn child be diagnosed with CMA. The use of Pepti Syneo together with his mother's past experience of CMA management allowed baby E's mother to get on top of his diagnosis early, and start the milk ladder in a timely fashion.

“Baby E tolerated Pepti Syneo well and its use alongside breastfeeding resulted in an improvement to his eczema and continued control of his gastrointestinal symptoms”

CONCLUSION

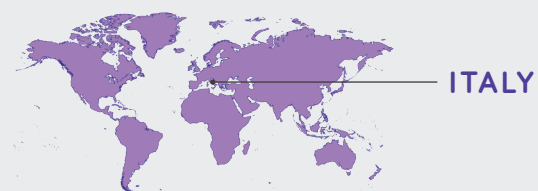
Baby E tolerated Pepti Syneo well and its use alongside breastfeeding (with his mother following a cow's milk elimination diet) resulted in an improvement to his eczema and continued control of his gastrointestinal symptoms. Baby E continued to grow well following the switch and the use of Pepti Syneo had a positive impact on his mother's management experience.

¹ Stalder J, Barbarot S, Wollenberg A, Holm E, De Raeve L, Seidenari S, Oranje A, Deleuran M, Cambazard F, Svensson A, Simon D, Benfeldt E, Reunala T, Mazereeuw J, Boralevi F, Kunz B, Misery L, Mortz C, Darsow U, Gelmetti C, Diepgen T, Ring J, Moehrenschrager M, Gieler U, Taieb A. Patient-Oriented SCORAD (PO-SCORAD): a new self-assessment scale in atopic dermatitis validated in Europe. *Allergy*. 2011;66(8):1114-1121.

INFANT WITH SEVERE, IMMEDIATE ALLERGIC REACTIONS

BABY F

Diego Peroni Paediatrician
Paediatric Dept, University of Pisa



PATIENT PROFILE

Breastfed IgE-mediated cow's milk allergic infant, with no family history of atopy, continued to grow well and saw symptom improvement within a month, including reduced dryness of skin, after switching to Pepti Syneo.

- IgE-mediated CMA
- Infant antibiotic use
- Dermatological symptoms
- Gastrointestinal symptoms
- Feeding difficulties

BACKGROUND

Baby F was born 40 weeks by spontaneous vaginal delivery and had no family history of atopy. At birth she was admitted to the Neonatal Intensive Care Unit (NICU) after a rise in inflammatory markers and a suspected infection. In the NICU baby F was treated with a systemic antibiotic and discharged home in good health after seven days. Baby F was breastfed for the first three months of life and presented with mild eczema. Baby F's mother had planned to introduce formula before substituting formula for

breastfeeding, in preparation for her return to work. At three months old, baby F trialled cow's milk formula and immediately developed skin symptoms of urticaria (hives) and angioedema (swelling beneath the skin). Her two subsequent trials of the formula also resulted in vomiting for ten and fifteen minutes, respectively. In all three trials, baby F refused to continue feeding and was more irritable afterwards. Baby F also presented with inconsolable crying.

MANAGEMENT

Baby F was prescribed antihistamine following each of her adverse reactions to cow's milk formula. Apart from the attempts to introduce cow's milk formula, baby F was breastfed for four and a half months. Baby F's IgE-mediated cow's milk allergy (CMA) was confirmed by skin prick tests. Her tests

for whole milk, casein, Alfa-lactoalbumin and Beta-lactoglobulin gave a wheel diameter of five, five, five and three millimetres respectively; all of which indicated an allergy¹. Her SCORAD (SCORing Atopic Dermatitis) tool result was 28², indicating moderate atopic dermatitis.

¹ For skin prick tests, an average wheel diameter above 3mm usually indicates an allergy.

Kido, J., Hirata, M., Ueno, H., Nishi, N., Mochinaga, M., Ueno, Y., Yanai, M., Johno, M. and Matsumoto, T., 2016. Evaluation of the Skin-prick Test for Predicting the Outgrowth of Cow's Milk Allergy. *Allergy & Rhinology*, 7(3), pp.e139-e143.

van der Valk, J., Gerth van Wijk, R., Hoorn, E., Groenendijk, L., Groenendijk, I. and de Jong, N., 2015. Measurement and interpretation of skin prick test results. *Clinical and Translational Allergy*, 6(8).

² Oranje A. Practical issues on interpretation of scoring atopic dermatitis: SCORAD Index, objective SCORAD, patient-oriented SCORAD and Three-Item Severity score. *Current problems in dermatology*. 2011; 41:149-155.

FOLLOW UP CARE

The aim of baby F's nutritional intervention was to find a safe formula for her to commence. The formula needed to allow normal growth to continue, cause a reduction in her existing eczema and not induce any new symptoms. Tolerance to the formula was important given baby F's mothers' decision to stop breastfeeding and switch to formula as the sole source of nutrition. **Pepti Syneo** was commenced under supervision in hospital at four and a half months, at 180ml four times a day. Baby F had good compliance with **Pepti Syneo** and consumed it with no issues.

After switching to **Pepti Syneo** baby F's symptoms visibly improved within a month. The dryness of her skin improved and her SCORAD score fell from 28 to 15. Baby F grew well whilst she was breastfed and continued to grow well, following normal growth percentiles, after switching to **Pepti Syneo** (growth chart on next page).

Baby F started weaning at five months, gradually introducing foods with the exceptions of milk and milk derivatives. Baby F has not yet developed tolerance to milk.



After switching to Pepti Syneo baby F's symptoms visibly improved within a month.

DISCUSSION

CMA is a frequent issue in paediatric clinical practice and diagnosis is essential to determine the correct therapeutic approach. Pepti Syneo is indicated where breastfeeding is not possible, and safe nutritional support is needed. Pepti Syneo prevents cow's milk exposure and the associated symptoms. It can also improve symptoms associated with other atopic diseases, such as atopic dermatitis, as it did in baby F; this could be due to Pepti Syneo's influence on the gastrointestinal (GI) microbiome.

In baby F's case, Pepti Syneo was recommended because it contains hydrolysed cow's milk proteins alongside synbiotics. The presence of synbiotics modifies the GI microbiome, potentially facilitating a faster tolerance of cow's milk; the acquisition of tolerance is a fundamental objective for patients and their families in infancy.



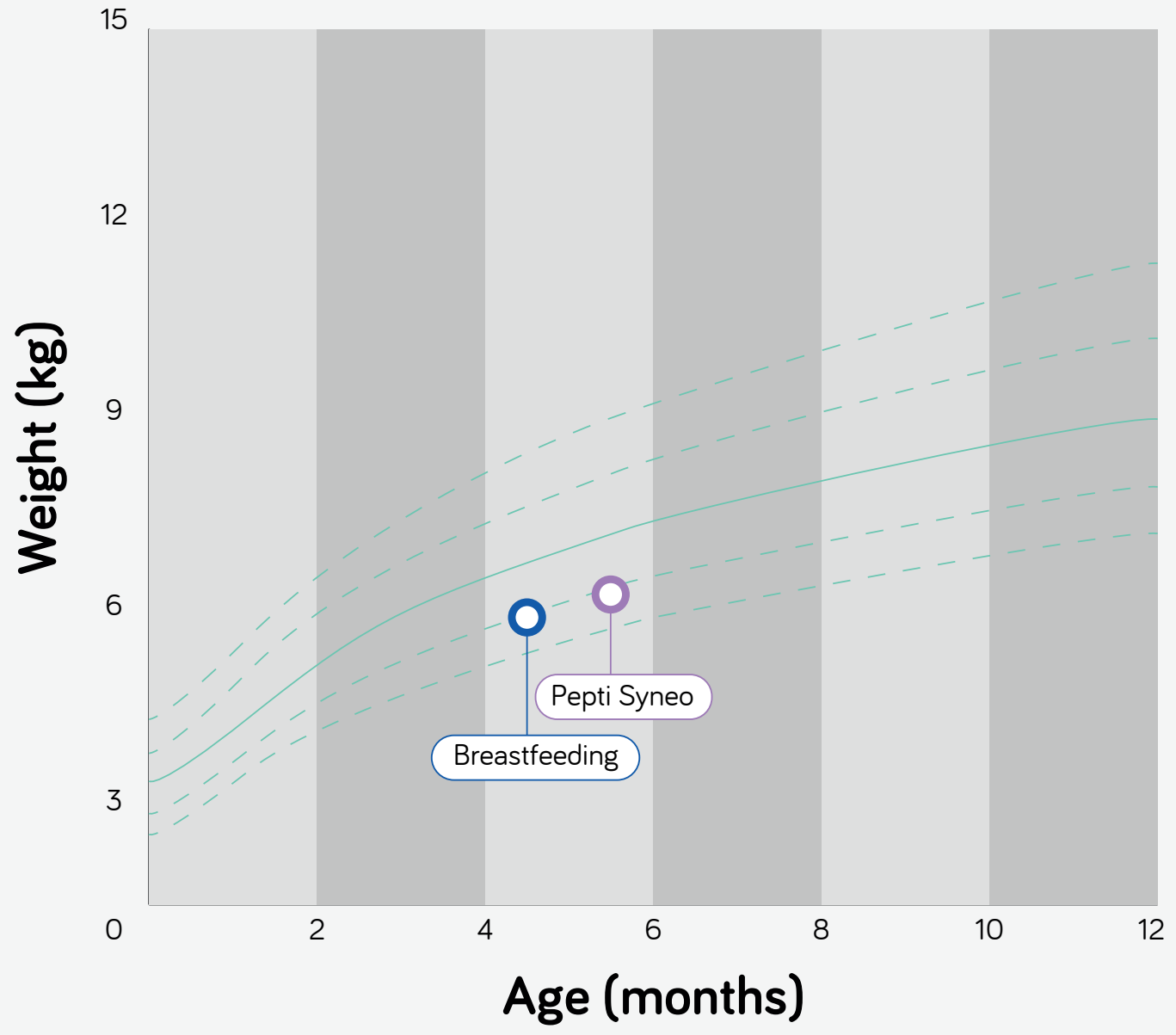
Baby F's mother was satisfied with the feed and had reduced anxiety now that baby F could tolerate the formula safely.

CONCLUSION

In this IgE-mediated CMA infant, commencing Pepti Syneo resulted in an improvement to her eczema within a month and facilitated continued normal growth without any additional symptoms. Baby F's mother was satisfied with the feed and had reduced anxiety now that baby F could tolerate the formula safely.

Case study continues on the next page.

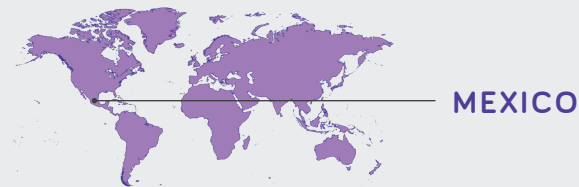
GROWTH CHART



CHALLENGES WITH AN ELIMINATION DIET IN A BREASTFED INFANT

BABY G

José Francisco Cadena León Paediatric Gastroenterologist
National Paediatrics Institute



PATIENT PROFILE

This non-IgE mediated cow's milk allergic infant was born at full term via caesarean section and was breastfed from the start of her life supplemented with standard infant formula. Breastfeeding (with the mother following a cow's milk elimination diet) in combination with Pepti Syneo didn't lead to a complete resolution of symptoms, so the infant was transitioned completely to Pepti Syneo which resulted in symptom improvement and improved quality of life.

- Born by caesarean section
- Non-IgE mediated CMA
- Family history of allergic rhinitis
- Maternal antibiotic use during pregnancy
- Exposure to infant formula within 24 hours of birth
- Dermatological symptoms
- Gastrointestinal symptoms
- Challenges with (maternal) elimination diet

BACKGROUND

Baby G was born at 39 weeks by caesarean section, weighing 2.95kg. Baby G's mother took antibiotics during her third trimester of pregnancy and has allergic rhinitis. From birth, baby G was breastfed and supplemented with a standard infant formula. At seven days old, baby G presented with irritability, colic, straining, refusal to feed, back arching after eating, gastroesophageal reflux (GER) (regurgitation

four times a day) and two episodes of intermittent laryngeal spasms. Baby's G straining typically lasted three to five minutes, with face redness (dyschezia) and pasty stools with mucus. Baby G was examined at 15 days old and found to have eczema on both cheeks, perianal erythema and slight abdominal distension.

MANAGEMENT AND FOLLOW UP CARE

The goal of baby G's nutritional intervention was to alleviate her symptoms and to prevent any complications, namely long or short term inflammatory or motility disorders. Given baby G's risk factors for cow's milk allergy (CMA) and her clinical symptoms, she was commenced on **Pepti Syneo**.

Baby G started **Pepti Syneo** at 15 days old, in combination with breastfeeding, and baby G's mother

followed a cow's milk elimination diet. There were no issues with the palatability, tolerance or acceptance of **Pepti Syneo**. Baby G's regurgitation, irritability and laryngeal spasms all became 50% less frequent, and her stool frequency normalised. However, baby G's mother had poor compliance to her elimination diet and it was recommended that baby G was exclusively fed by **Pepti Syneo** for ten days; this resulted in a 90% improvement to her symptoms.

MANAGEMENT AND FOLLOW UP CARE (CONT.)

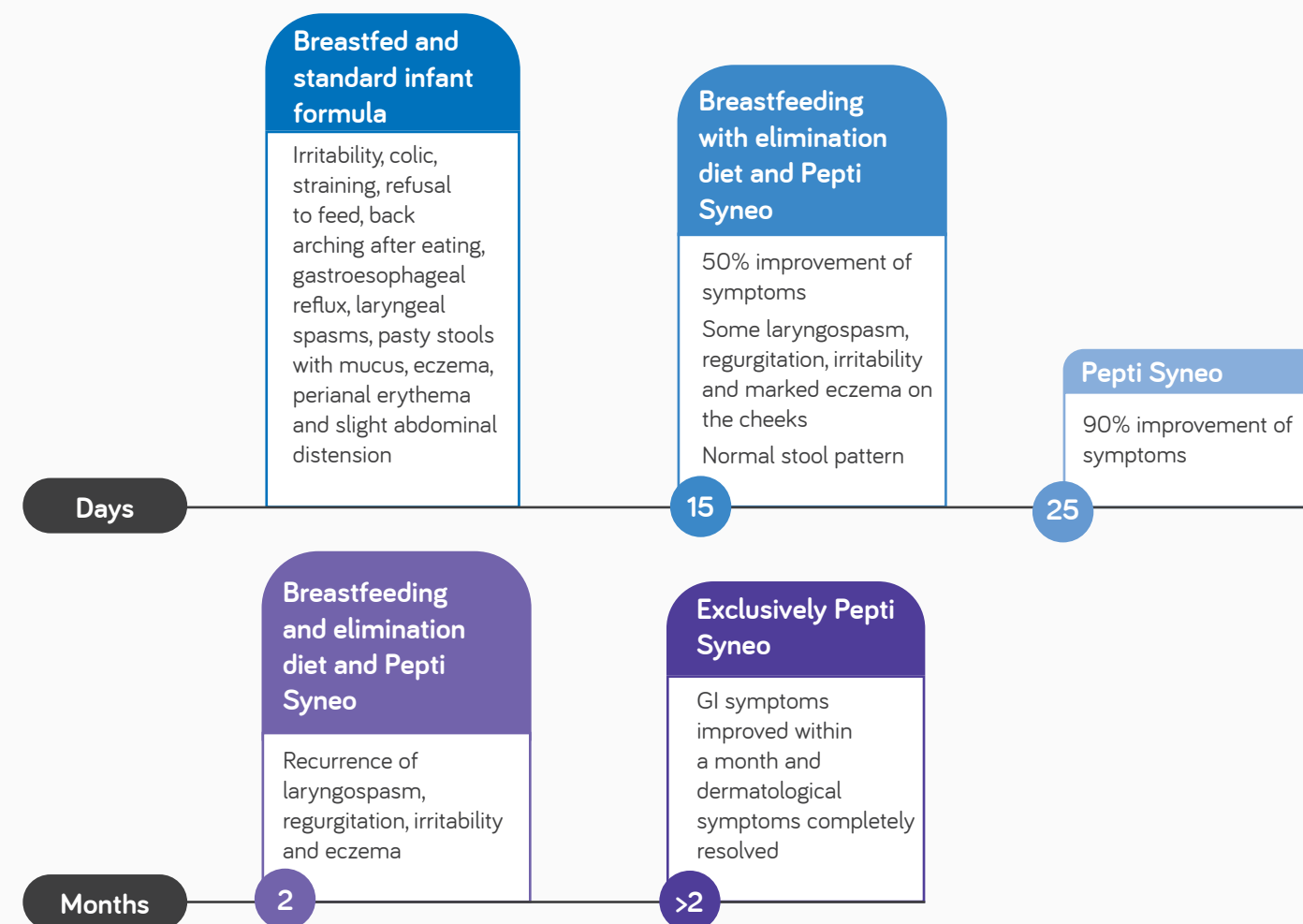
After ten days breastmilk was re-introduced, with baby G's mother on a strict cow's milk protein elimination diet. Her mother had poor compliance to the elimination diet and the reintroduction of breastmilk led to a recurrence of baby G's laryngospasm, regurgitation, irritability and eczema. Consequently, after 48 hours breastfeeding was discontinued and baby G was fed again exclusively with **Pepti Syneo**. Once exclusively on **Pepti Syneo**, baby G's gastrointestinal (GI) symptoms were improved within a month and her dermatological symptoms completely resolved. As a result of her symptom improvement following cow's milk restriction, baby G was diagnosed with non-IgE CMA.

At five months old, baby G was given a cookie containing cow's milk protein and her GI and dermatological symptoms returned. Her mother was re-educated about baby G's diet and baby G was prescribed three days of an anti-histamine. Although accidental, her reaction to cow's milk at five months demonstrated that she hadn't yet developed tolerance. At six months complementary feeding was introduced (excluding cow's milk), and baby G's tolerance will be assessed at 12 months old.

She had normal growth and neurological development throughout.

“Once exclusively on **Pepti Syneo**, baby G's gastrointestinal (GI) symptoms were improved within a month and her dermatological symptoms completely resolved.”

TIMELINE



Case study continues on the next page.

DISCUSSION

In the first months of baby G's life her parents were stressed and anxious because of the multiple symptoms their infant was displaying. At first, baby G's mother trialled following an elimination diet whilst breastfeeding but due to her poor compliance this wasn't successful. However, once baby G was exclusively fed with Pepti Syneo, their stress reduced and overall quality of life improved. The impact of Pepti Syneo's synbiotics is seen in the resolution of baby G's dermatological symptoms and the improvement in her GI symptoms.

Non-IgE mediated CMA can be present from the first weeks of life. The presence of genetic or epigenetic risk factors and symptoms help to make an early diagnosis, and allow an appropriate treatment plan to be implemented. The management of CMA aims to achieve oral tolerance and encourage optimal development within the first six months of infants' lives, known as the 'window of opportunity'.

Where infants are partially breastfed or exclusively formula fed, an extensively hydrolysed formula with synbiotics may help infants to develop oral tolerance. Once the formula is introduced, it may take one to two weeks for symptoms to resolve, and healthcare professionals should be mindful of a patient's compliance to the rest of their diet.



Overall, baby G's parents and healthcare team were very satisfied with her health.

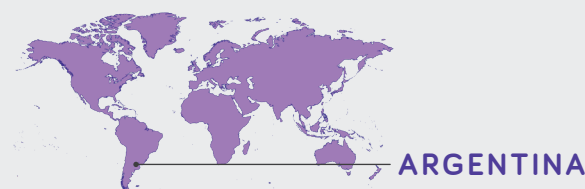CONCLUSION

Baby G had a complete resolution of her dermatological symptoms and improvement in her GI symptoms within one month of switching to feeding exclusively with Pepti Syneo. Overall, baby G's parents and healthcare team were very satisfied with her health.

MIXED FED INFANT WITH MFA AND SEVERE ATOPIC DERMATITIS

BABY H

María Eugenia Gervasoni Paediatrician/Allergy Immunologist
Hospital de Niños Víctor J. Vilela



ARGENTINA

PATIENT PROFILE

This infant, born at 39 weeks by caesarean section, has multiple food allergies (MFA) to cow's milk, egg and peanut. After exclusive breastfeeding (with the mother following an elimination diet) didn't lead to symptom resolution and the infant failed to thrive, Pepti Syneo was introduced to supplement breastfeeding (mother eliminating cow's milk, eggs and peanuts). Within a month, this switch resulted in an improvement in growth and dermatological and gastrointestinal symptoms in baby H.

- IgE and non-IgE mediated CMA
- Mixed fed infant
- Multiple food allergies
- Born by caesarean section
- Family history of atopic dermatitis and asthma
- Severe atopic dermatitis
- Gastrointestinal symptoms
- Failure to thrive

BACKGROUND

Baby H was born at 39 weeks by elective caesarean section weighing 3.2kg. He has a family history of atopic dermatitis and asthma. From birth baby H was breastfed, and from four days until one month old, baby H was breastfed and supplemented with a standard infant formula. At 15 days old, baby H presented with urticarial plaques (hives), atopic dermatitis, colic, crying, vomiting, gastroesophageal reflux (GER) and had mucus in his stools. Proton

pump inhibitors (PPI) were prescribed in an attempt to manage baby H's GER symptoms. At one month old, baby H's symptoms persisted; his formula was discontinued and he was exclusively breastfed without his mother following an elimination diet. At four months old, baby H was referred on by his paediatrician and dermatologist as his symptoms hadn't resolved.

MANAGEMENT

At four months old, baby H was referred with suspected food allergy and moderate atopic dermatitis which was difficult to control with dermatological treatment. On examination, baby H had eczema on his cheeks, torso and arms and seborrheic dermatitis on his scalp and forehead. His SCORAD (SCORing Atopic Dermatitis) score was 49.40¹, indicating severe atopic dermatitis. He was

irritable with a slightly tender abdomen, hyperactive bowel sounds and perianal erythema. Baby H was recommended to continue with his dermatologic treatment and his mother was recommended to follow an elimination diet, excluding milk and eggs as these are the main food allergens in Argentina.

At six months old, complementary foods were introduced (excluding milk and eggs) and baby H's PPI's were stopped as his GER was improved.

At baby H's follow-up appointment at seven months old, his symptoms were improved but he showed failure to thrive and had persistent atopic dermatitis, colic and mucus containing stools (type 7 on the Bristol stool chart²). Baby H underwent skin prick testing³ and serum specific IgE testing. Baby H

showed a positive result to cow's milk (10mm, 3 mUI/ml), alpha-lactalbumin (5mm, 1 mUI/ml), beta-lactoglobulin (8mm, 1.8 mUI/ml), casein (5mm, 1.2 mUI/ml), egg white (9mm, 3.2 mUI/ml), egg yolk (7mm, 2.5 mUI/ml), ovalbumin (8mm, 3.1 mUI/ml), ovomucoid (7mm, 3 mUI/ml) and peanut (5mm, 2 mUI/ml). He was diagnosed with mixed IgE and non-IgE mediated allergy to cow's milk, egg and peanut.

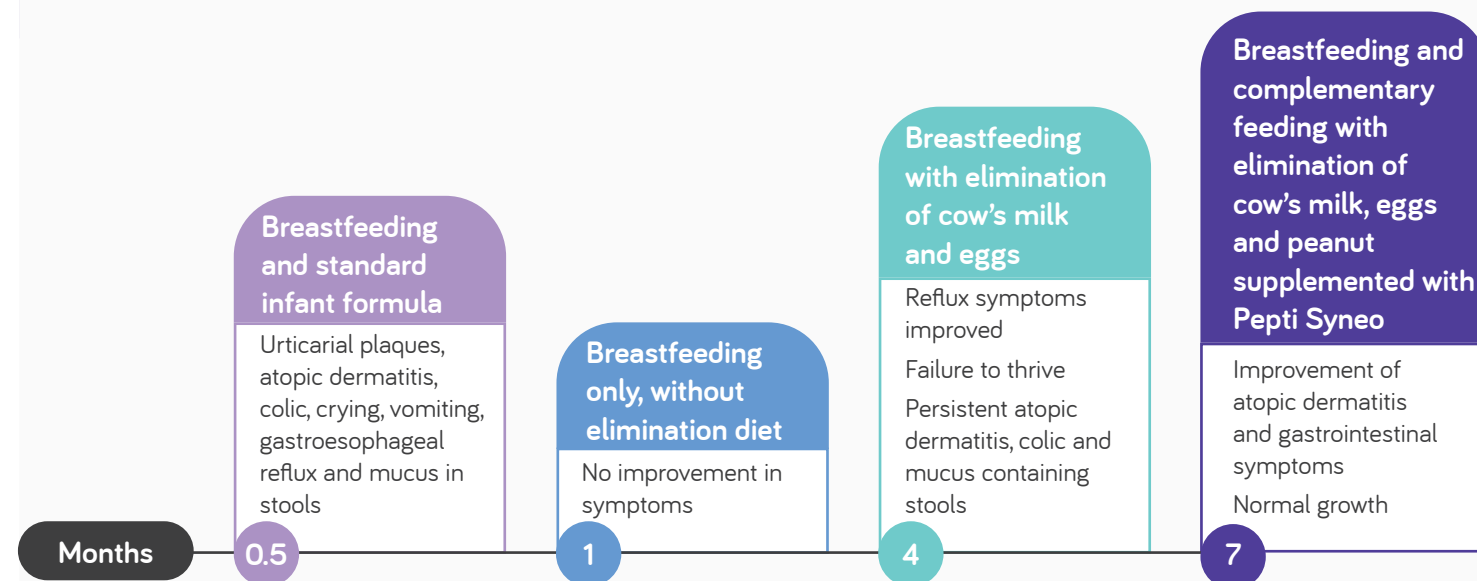
FOLLOW UP CARE

After baby H's allergy diagnosis, it was recommended that both baby H and his mother eliminate peanuts from their diets in addition to milk and eggs. In view of baby H's failure to thrive and his suspected intestinal dysbiosis, **Pepti Syneo** was commenced to supplement breastfeeding. Baby H was also referred onto a nutrition specialist for follow-up. Baby H tolerated and adhered to **Pepti Syneo** well and achieved his target volume of 720ml/day. One month after starting **Pepti Syneo**, baby H's atopic dermatitis was improved; his SCORAD score fell

to 9.14 indicating mild atopic dermatitis. His colic also resolved and his stools reduced in frequency, no longer contained mucus and were a normal consistency (type 5 on the Bristol stool chart²). Baby H had no infections and his growth recovered.

Baby H has not yet developed tolerance to cow's milk; he accidentally ingested cow's milk and urticarial plaques immediately appeared on his face, followed by an outbreak of atopic dermatitis and mucus in his stools the next day. He is planned to continue **Pepti Syneo** and his elimination diet, with regular review.

TIMELINE



Case study continues on the next page.

² Lewis S, Heaton K. Stool Form Scale as a Useful Guide to Intestinal Transit Time. Scandinavian Journal of Gastroenterology. 1997;32(9):920-924. For skin prick tests, an average wheel diameter above 3mm usually indicates an allergy.

³ Kido, J., Hirata, M., Ueno, H., Nishi, N., Mochinaga, M., Ueno, Y., Yanai, M., Johno, M. and Matsumoto, T., 2016. Evaluation of the Skin-prick Test for Predicting the Outgrowth of Cow's Milk Allergy. Allergy & Rhinology, 7(3), pp.e139-e143.

van der Valk, J., Gerth van Wijk, R., Hoorn, E., Groenendijk, L., Groenendijk, I. and de Jong, N., 2015. Measurement and interpretation of skin prick test results. Clinical and Translational Allergy, 6(8).

¹ Oranje A. Practical issues on interpretation of scoring atopic dermatitis: SCORAD Index, objective SCORAD, patient-oriented SCORAD and Three-Item Severity score. Current problems in dermatology. 2011; 41:149-155

DISCUSSION

In the first few months of life, baby H's symptoms meant that baby H and his family had a poor quality of life. If baby H had been referred on earlier, the elimination diet and Pepti Syneo could have been commenced sooner, leading to an earlier improvement in baby H's symptoms. Once Pepti Syneo was commenced, baby H and his family's quality of life was significantly improved; his colic resolved and he was less irritable and cried less.

Baby H's severe atopic dermatitis was improved to only mild atopic dermatitis on Pepti Syneo, his colic resolved and his stools reduced in frequency, and were a normal consistency. Baby H had no infections and his growth recovered.

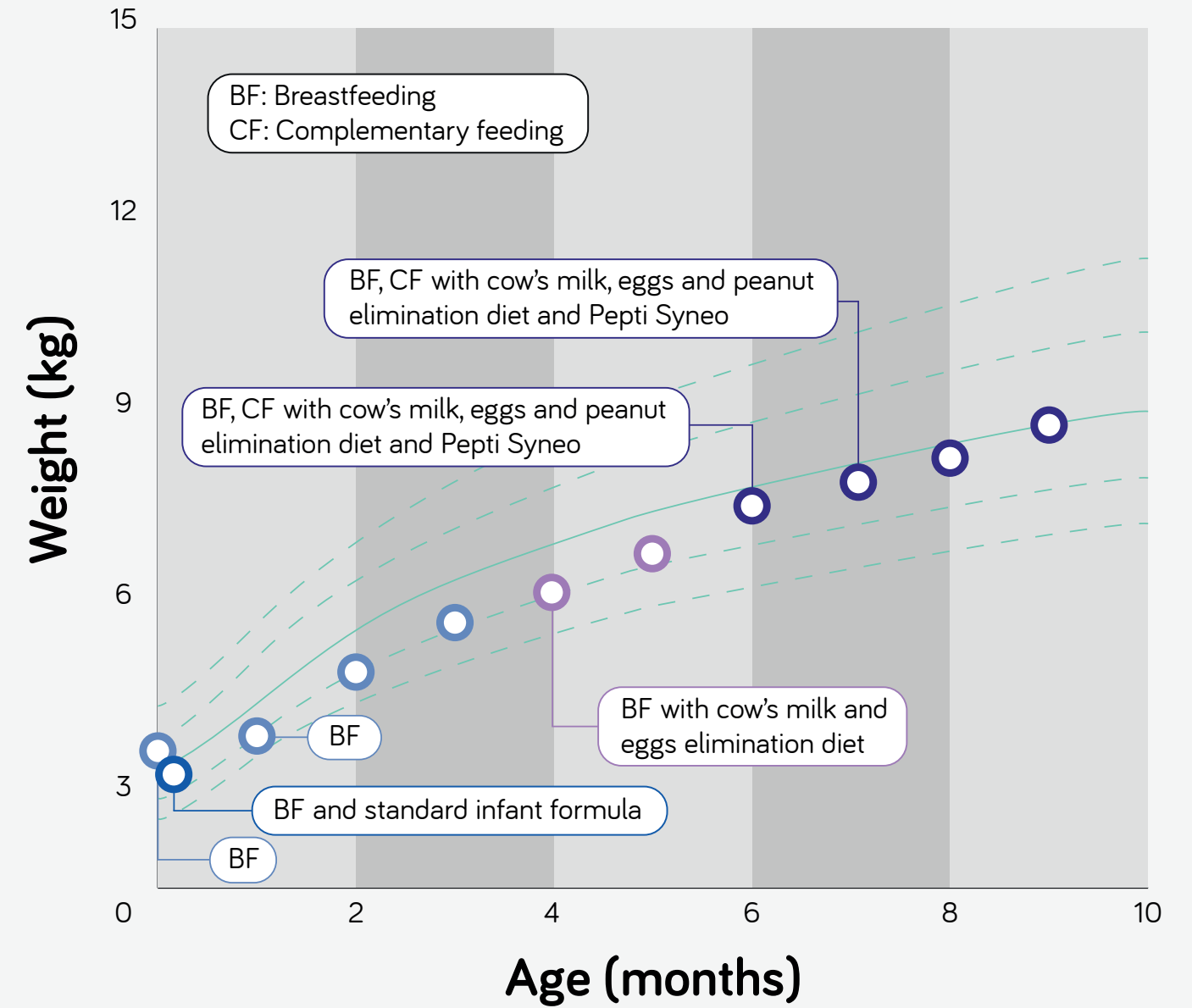
In view of baby H's failure to thrive and his suspected intestinal dysbiosis, Pepti Syneo was commenced to supplement breastfeeding.

Baby H presented with a number of risk factors for food allergy such as a caesarean section birth, early use of formula (from four days to one month old), a family history of allergies and being prescribed PPIs in his first months of life. It's important that infants are referred onto specialists early if they don't improve with the basic treatments; early diagnosis and treatment of food allergies gives an opportunity to prevent failure to thrive. The use of special formula with synbiotics for cow's milk allergy (CMA) needs to be considered as a good nutritional intervention to address dysbiosis.

CONCLUSION

Baby H had good growth and saw an improvement in his dermatological and gastrointestinal symptoms after he and his mother eliminated milk, eggs and peanuts and baby H began Pepti Syneo to supplement breastmilk. Baby H tolerated Pepti Syneo well and baby H and his families' quality of life improved significantly.

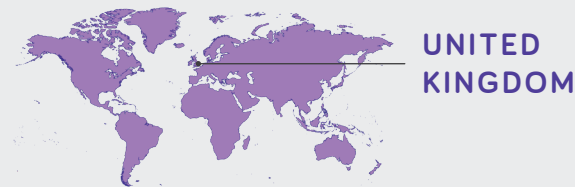GROWTH CHART



INFANT WITH PERSISTENT CONSTIPATION ON AN EHF WITHOUT SYNBIOTICS

BABY I

Catherine Casewell Specialist Paediatric Dietitian



PATIENT PROFILE

Formula fed infant who was born prematurely by caesarean section with non-IgE mediated cow's milk allergy (CMA) and symptomatic on a casein-based extensively hydrolysed formula (eHF). The infant saw a quick resolution of their gastrointestinal symptoms and reduction in their use of laxatives following a switch to Pepti Syneo.

- Non-IgE mediated CMA
- Prematurely born infant due to intrauterine growth retardation
- Gastrointestinal symptoms
- Dermatological symptoms
- Symptomatic on eHF

BACKGROUND

Baby I was born preterm at 36 weeks by caesarean section with no complications, due to intrauterine growth retardation. Baby I was born on the 0.4th centile for weight and was formula fed from day one, starting with a standard infant formula. At seven days old, baby I presented to the emergency room with poor feeding (reduced from 50-60mls every three hours to 20mls) and a high incidence of flatulence. They were admitted to the paediatric ward for 24-

hour observation and discharged home the following day as feeding had improved. From four weeks old baby I's weight began to increase, moving towards the 25th-50th centile. At four weeks old, baby I presented to the general practitioner (GP) with worsening symptoms of reflux, vomiting, constipation and mild patches of dry skin, all of which had been present since birth. The GP suspected non-IgE mediated CMA.

MANAGEMENT

In an effort to alleviate baby I's gastrointestinal and dermatological symptoms, the GP commenced a probiotic containing eHF, alongside Gaviscon (alginate). Baby I's reflux symptoms persisted and Gaviscon was changed to Omeprazole (proton pump inhibitor). On some days, baby I was being fed up to 200mls per kg of body weight per day, so overfeeding may have contributed to the reflux and discomfort. Baby I was referred onto a paediatrician to support with the management of their reflux and constipation.

Following the switch to Omeprazole, the combination of probiotic containing eHF and medication was effective at managing baby I's reflux and vomiting. However, baby I's dry skin and constipation persisted. To manage the ongoing constipation daily laxatives (half a sachet of Laxido) were prescribed. The laxatives were effective and baby I's bowels began to open regularly, although when the laxatives were not taken baby I's stools became hard (type one on the Bristol Stool Chart¹).

¹ Lewis S, Heaton K. Stool Form Scale as a Useful Guide to Intestinal Transit Time. Scandinavian Journal of Gastroenterology. 1997;32(9):920-924.

MANAGEMENT (CONT.)

Baby I's suspected non-IgE mediated CMA was confirmed when their symptoms returned after being challenged with cow's milk. At six months old, baby I was referred to the dietitian for ongoing support with allergy management. The aim of dietetic care was to provide a cow's milk free diet for baby I, to manage baby I's symptoms, and to identify appropriate cow's milk alternatives which allow for normal growth to be

maintained and nutritional requirements to be met. Complementary feeding, excluding cow's milk containing foods, was successfully introduced at six months old. A particular emphasis was placed on fibre containing foods considering baby I's constipation. Solids soon became preferable to formula for baby I and they began to refuse the formula.

FOLLOW UP CARE

To improve baby I's formula intake and constipation, baby I's parents agreed to switch them onto a synbiotic containing eHF, **Pepti Syneo**. This was well tolerated and baby I was able to meet their target volume of around 400mls of **Pepti Syneo**, alongside their three meals a day.

After eleven days on **Pepti Syneo**, baby I was passing softer stools (type six on the Bristol Stool Chart¹), their bowels were opening normally without straining and baby I's laxatives were able to be reduced from daily to every two days. After four weeks of **Pepti Syneo**, baby I's reflux and vomiting had both completely resolved, their constipation continued to be well managed, and they continued to grow well (tracking along the 75th centile for weight and length). However, baby I continued to experience mildly dry

skin and they developed a fungal skin infection which required Daktarin (anti-fungal medication).

At nine months old baby I was challenged with cow's milk, using the iMAP milk ladder as a guide. Baby I progressed quickly through the stages (advancing a step every three to four days) but as they progressed, more laxatives were needed. It was recommended that baby I return to a stage where laxatives didn't need to be increased and that they be re-trialled three months later. Three months later, just before baby I was one year old, they acquired tolerance to cow's milk and **Pepti Syneo** was successfully switched to standard infant formula. At this stage, baby I's symptoms had fully resolved, and all their medications had ceased. Baby I was enjoying meals containing cow's milk, and these meals met all their nutritional requirements.

DISCUSSION

The aim of baby I's management was to provide symptom relief from the constipation, reflux, and vomiting that baby I was experiencing, despite the use of medication and eHF. Initially, overfeeding may have played a role in baby I's reflux and discomfort as some days baby I was fed up to 200mls per kg of body weight per day.

Following the switch to Pepti Syneo baby I's parents were satisfied that the severity of baby I's symptoms had reduced, as well as the need for laxatives. Baby I tolerated the target volume of Pepti Syneo with no concerns, until the taste for solids became preferable.

“After eleven days on Pepti Syneo, baby I was passing softer stools, their bowels were opening normally without straining and laxatives were able to be reduced from daily to every two days”

“Baby I tolerated the target volume of Pepti Syneo with no concerns”

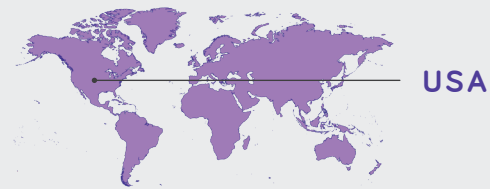
CONCLUSION

Baby I tolerated Pepti Syneo well and its use helped relieve baby I's gastrointestinal symptoms and reduce their medication usage. Following the switch, baby I continued to grow well and was subsequently able to incorporate and tolerate cow's milk in their diet.

INFANT WITH SEVERE ATOPIC DERMATITIS, MFA, GROWTH FAILURE AND LOOSE STOOLS

BABY J

Raquel Durban Registered Dietitian
Carolina Asthma & Allergy Center



PATIENT PROFILE

An infant with multiple food allergies (MFA) including IgE-mediated cow's milk allergy (CMA), who previously refused a hypoallergenic formula tolerated Neocate Syneo Infant¹. Following the switch to Neocate Syneo the infant's severe atopic dermatitis (eczema) and loose stools resolved and he experienced catch-up growth.

- IgE-mediated CMA
- Peanut allergy
- Faltering growth
- Dermatological symptoms
- Gastrointestinal symptoms
- Symptomatic on breastmilk (mother following elimination diet)

BACKGROUND

Baby J was exclusively breastfed from birth. At two month old baby J was seen by a dermatologist who diagnosed him with atopic dermatitis. At five months old, baby J's eczema was widespread, on

his face, arms, legs, torso and most severely on his cheeks, thighs and ankles. Baby J also presented with loose stools.

MANAGEMENT

At two months old, in an effort to treat baby J's newly diagnosed atopic dermatitis, baby J was prescribed topical creams. However, these were not as effective as his mother or the dermatologist had hoped. As baby J's mother was breastfeeding, she trialed an elimination diet excluding milk and soy, after hearing about this method from an online support group. However, after two weeks no improvement was seen in baby J's symptoms and she reintroduced milk and soy in her diet.

At five months old, baby J's eczema was widespread and his mother self-referred him to an allergy specialist. Around six months old, baby J commenced complementary feeding. Baby J underwent skin prick testing which showed a strong sensitivity to peanut

(epinephrine was given) and a mild sensitivity to cow's milk. Until the allergy testing, baby J hadn't been exposed to peanuts and had been tolerating cow's milk based yoghurt without developing hives or swelling. However, he had been consuming packaged infant foods, which may have contained, or been contaminated with, allergens. Following the allergy testing, baby J's family were educated on how to avoid milk and peanuts and, empirically, tree nuts were also advised to be avoided. Baby J was commenced on 400 international units of vitamin D, as

¹ Neocate Syneo Infant is the USA formulation equivalent to Neocate Syneo in EU/Rest of world

MANAGEMENT (CONT.)

recommended by the National Eczema Association. Baby J's mother was keen to explore supplemental formula feeding, to allow others to be involved in baby J's feeding without her expressing breast milk. Baby J was commenced on a hypoallergenic infant formula in light of his food allergies and loose stools but he refused it. His mother trialed two more weeks of

following a cow's milk elimination diet but did not find this to be helpful, and returned again to her normal diet. Baby J's widespread eczema and loose stools

FOLLOW UP CARE

At seven and a half months old, baby J started a gradual transition onto an amino acid formula with synbiotics, **Neocate Syneo**; his final target volume was 30fl oz (887 ml) per day which provides 600kcal (baby J's estimated daily requirements: 710kcal, 11g protein). Education was also provided regarding allergen free dietary alternatives for baby J and his mother.

Two weeks later, at eight months old, baby J was tolerating 28fl oz (828ml) of **Neocate Syneo** per day. His stools had improved, with three days of formed stools, and his eczema had resolved with the exception of the eczema on his cheeks; this persistent eczema was likely due to his mother continuing to breastfeed for comfort without following

an elimination diet, as was her preference. Baby J achieved his target volume of **Neocate Syneo** (30fl oz/887ml), and following the success of **Neocate Syneo**, baby J's mother felt more confident to wean him off breastmilk completely.

At eight months old, baby J's weight remained static on the 10-25th percentile. However, in the months that followed he gained weight and experienced catch-up growth; at his twelve month appointment baby J was in the 50th-75th percentile for weight.

“
His stools had improved and his eczema had resolved with the exception of the eczema on his cheeks

DISCUSSION

Finding the appropriate hypoallergenic formula for baby J, Neocate Syneo, lead to an improvement in his symptoms and in the quality of life of his family. His family's confidence was improved further after seeing baby J's weight gain and catch-up growth (between eight and ten months) following the switch to Neocate Syneo.

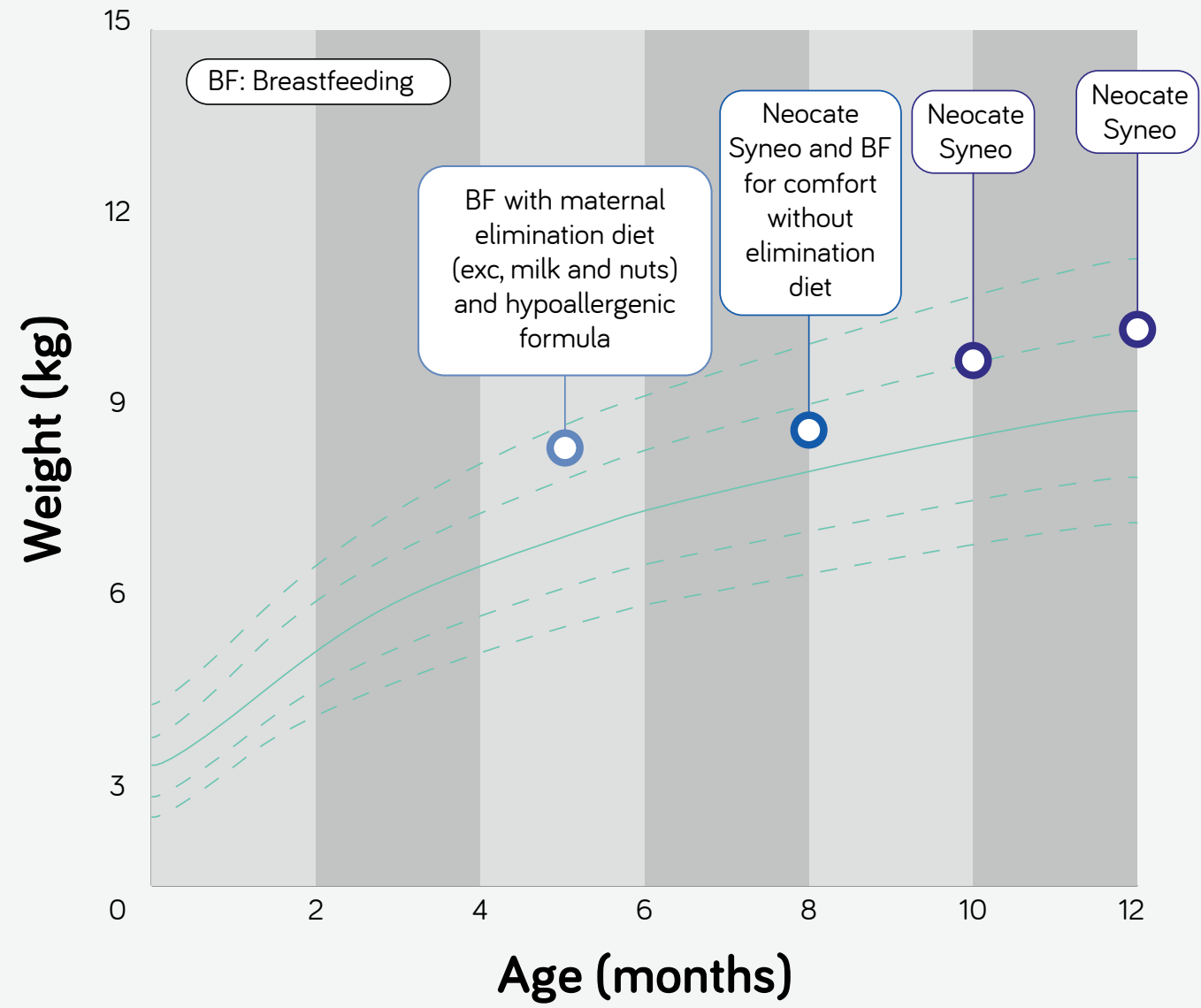
“
The switch also allowed for catch-up growth to occur and improved his family's quality of life

CONCLUSION

In this infant with IgE-mediated CMA and peanut allergy, a switch to Neocate Syneo resulted in the resolution of both his gastrointestinal and dermatological symptoms. The switch also allowed for catch-up growth to occur and improved his family's quality of life.

Case study continues on the next page.

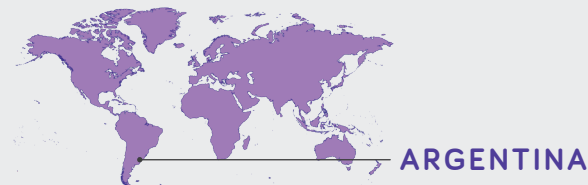GROWTH CHART



INFANT WITH PERSISTENT DIARRHOEA AND BLOOD IN STOOL ON AN EHF

BABY K

Mónica del Compare Paediatric Gastroenterologist
Paediatric Hospital Federico Falcón Del Viso Pilar



PATIENT PROFILE

This non-IgE mediated cow's milk allergic infant, born at 40 weeks by caesarean section, displayed symptoms of rectal bleeding and diarrhoea. After exclusive breastfeeding, exclusive breastfeeding with the infant's mother excluding allergens and breastfeeding supplemented with multiple different formulas had failed to resolve the infants' symptoms, a switch to Neocate Syneo resulted in fast symptom resolution and satisfied parents.

- Non-IgE mediated CMA
- Born by caesarean section
- Family history of allergy to penicillin and anti-inflammatories
- Infant antibiotic use
- Gastrointestinal symptoms
- Symptomatic on an eHF, an AAF and when breastfed with mother following an elimination diet

BACKGROUND

Baby K was born at 40 weeks by an elective caesarean section, weighing 3.39kg. Baby K had a family history of atopy as her father and grandfather were allergic to penicillin and anti-inflammatories. Baby K was breastfed from birth but lost 12% of her body weight within the first 72 hours of life and

weighed 2.891kg on discharge. In light of baby K's weight loss and her mother's low production of breast milk, at discharge she was started on a standard infant formula to supplement breastfeeding. At three weeks old, baby K presented with rectal bleeding and diarrhoea.

MANAGEMENT

The first stage of K's treatment was to rule out other diseases; her stool culture did not contain adenovirus, rotavirus or growth of any pathogenic bacteria, her routine blood tests were normal. A maternal elimination diet avoiding cow's milk and soy was recommended. After seven days there was no symptom improvement and the mother was recommended to additionally eliminate egg, wheat, fish and nuts. As baby K continued to experience bleeding, she underwent scintigraphy (a gamma scan) which ruled out Meckel's diverticulum. Ideally,

baby K would have also had an endoscopy, but her mother declined this. After ruling out other potential diseases, non-IgE mediated cow's milk allergy (CMA) was suspected.

The aim of Baby K's treatment was for her to achieve optimal nutrition, stop bleeding, avoid exposure to milk, and avoid exposure to other breast milk allergens.

When Baby K was 21 days old, she was weaned off standard infant formula and switched to exclusive

MANAGEMENT (CONT.)

breastfeeding. However, Baby K's rectal bleeding and diarrhea persisted and at 50 days of age, breastfeeding was supplemented with a casein-based, low-lactose, high medium chain triglyceride (MCT), extensively hydrolyzed formula (eHF). The eHF had no effect on baby K's symptoms and she was switched onto an amino acid formula (AAF), to supplement

breastfeeding. As a result of her restrictive elimination diet, baby's K mother lost over ten kilos in weight. In light of this significant weight loss, and to ensure that no other component of baby K's mothers' diet whilst breastfeeding was causing the bleeding, baby K was prescribed Neocate Syneo, and breastfeeding was suspended for one week to evaluate the results.

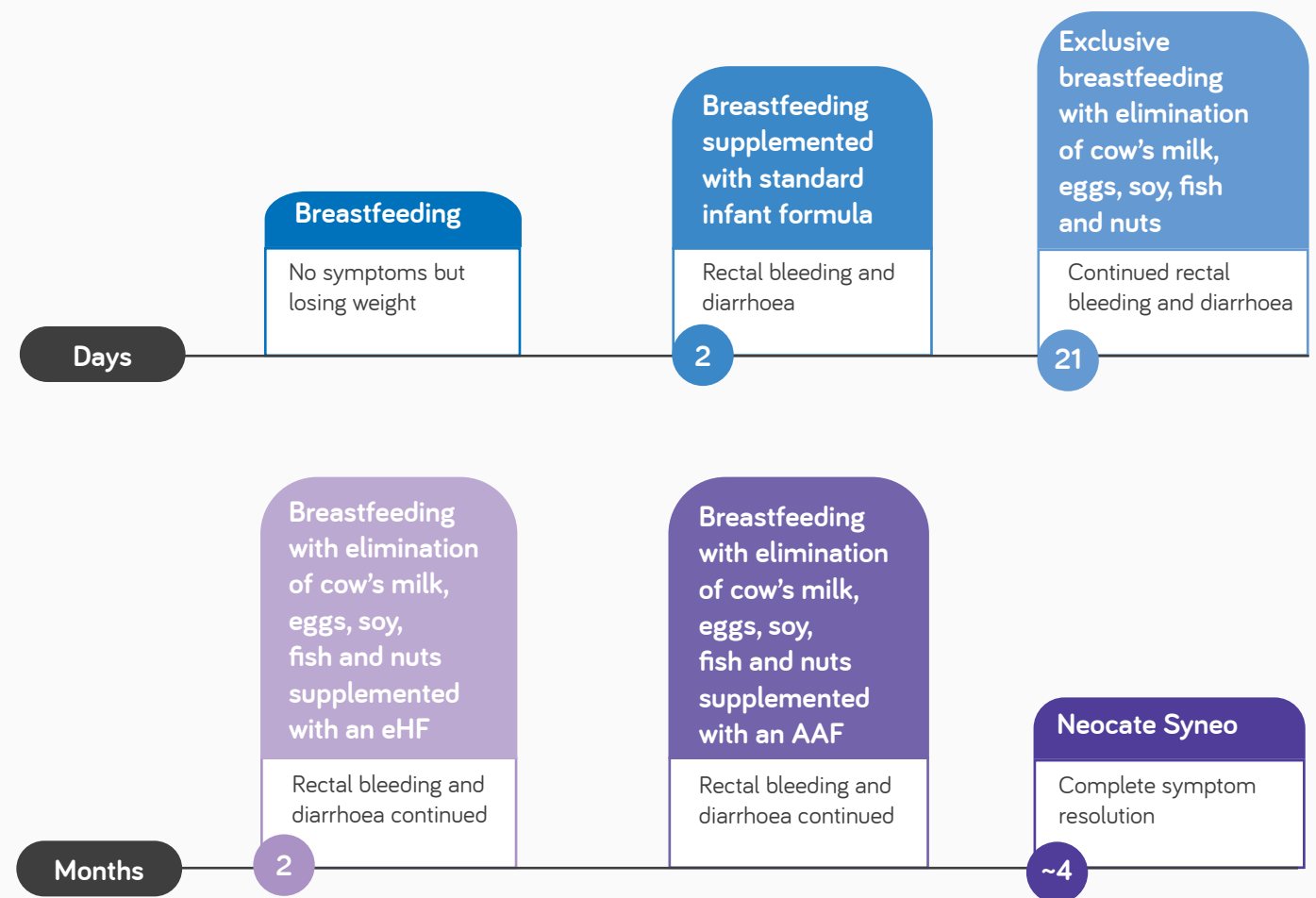
FOLLOW UP CARE

The switch to **Neocate Syneo** was successful and within a week of commencing **Neocate Syneo** baby K's rectal bleeding had stopped. Baby K's diarrhoea also quickly resolved; her stools were a normal colour and consistency and no effort was required to defecate.

At six months old semi-solid foods were introduced and at ten months old baby K was challenged to

determine if she'd acquired tolerance to milk. To begin with she was stepped down to an eHF which was tolerated well and after a month she switched to a partially hydrolysed formula (pHF). After tolerating the pHF well, at 12 months old she started on a lactose free formula. Baby K was trialed with cow's milk at 12 months old and tolerated it with no issues. At 15 months she was switched onto a young child formula containing cow's milk protein and cow's milk containing foods were introduced with no issues.

TIMELINE



Case study continues on the next page.

DISCUSSION

Baby K's parents were emotionally struggling with seeing their daughter experience bleeding and diarrhoea. They found themselves constantly anxious, always needing to be alert and not able to enjoy time with their daughter. Following the complete resolution of baby K's symptoms after commencing Neocate Syneo, her family were very grateful; baby K's mother regained the weight she had lost and the whole family were much calmer and able to enjoy time with baby K.

Making correct decisions is essential to maintaining a good doctor-patient-family relationship; in this case the doctor-patient relationship was improved as a result of baby K's successful symptom resolution.

It is important to listen to the infant's parents when making medical decisions. In this case the mothers' health was not good, she was losing weight and both parents were stressed. Sometimes medical decisions need to be made by drawing on experience and evaluating what is best for both the infant and their

family. Although it was a difficult decision to suspend breastfeeding, it was made in agreement with baby K's parents. For baby K, the combination of synbiotics in Neocate Syneo was thought to be ideal as she presented with damage in her intestinal mucosa.



*In light of this significant weight loss, and to ensure that no other component of baby K's mothers' diet whilst breastfeeding was causing the bleeding, baby K was prescribed **Neocate Syneo**.*

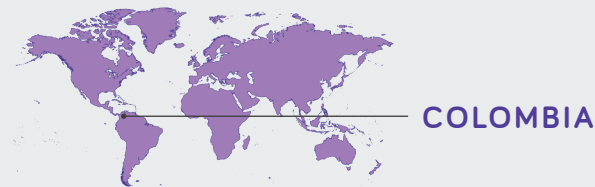
CONCLUSION

Baby K saw a fast resolution of her rectal bleeding and diarrhoea following the switch to Neocate Syneo. Baby K's mother was able to regain the weight she had lost whilst on her restrictive elimination diet and the whole family was much calmer. The use of Neocate Syneo led to excellent satisfaction from the patient and healthcare team.

TWINS BORN PREMATURELY WITH SKIN AND GI SYMPTOMS AND FALTERING GROWTH

BABY L AND M

Juan Pablo Riveros López Paediatric Gastroenterologist
Private Juan Pablo Riveros



PATIENT PROFILE

These infant twins with non-IgE mediated cow's milk allergy (CMA) were born preterm by caesarean section with no family history of allergies. Switching to Neocate Syneo resulted in a rapid and complete resolution of their gastrointestinal (GI) symptoms and allowed catch-up growth to occur.

- Twins, born prematurely
- Non-IgE mediated CMA
- Faltering growth (baby L & M)
- Gastrointestinal symptoms (baby L & M)
- Dermatological symptoms (baby L only)

BACKGROUND

Baby L and M are twin girls who were born preterm at 33 weeks by caesarean section with intrauterine growth retardation. Baby L and M weighed 1325g and 1560g respectively at birth; baby L is the oldest twin. Their mother had COVID-19 pneumonia at the time of birth, and they have no family history of atopy. Both twins had neonatal jaundice and received supplemental oxygen due to transient tachypnea

(rapid breathing). Both were fed with a comfort infant formula via a gastric tube from birth. At three days old they presented with severe abdominal pain (both), anal erythema (both), irritability (both), blood in stools (baby L), diarrhoea (both), crying (both), bloating (both), atopic dermatitis (baby L) and colic (baby L). Both twins were admitted to the neonatal intensive care unit (NICU).

MANAGEMENT

In the NICU, necrotizing enterocolitis was ruled out and both twins were suspected to have food protein-induced enterocolitis syndrome (FPIES). Baby L and M were both recommended to be exclusively orally fed with an amino acid formula (Neocate LCP) and were discharged home after 14 and 15 days, respectively.

35 days after discharge from the newborn unit, both infants underwent a supervised provocation allergy test with a comfort infant formula. Following the test, baby L presented with abdominal distention and a small amount of blood in her stools, and baby M presented with abdominal distention and diarrhoea. The reactions confirmed both infants' suspected diagnoses of non-IgE mediated CMA.

FOLLOW UP CARE

The aim of the nutritional management in both infants was to achieve a good nutritional status, to achieve catch up growth and to control their CMA symptoms. At their first consultation, baby L was diagnosed with malnutrition and stunting, and baby M was at risk of malnutrition and stunting. Following the infants' confirmed diagnoses of CMA, both infants were started on an amino acid formula with synbiotics, **Neocate Syneo**, 75-100ml eight times a day. **Neocate Syneo** was tolerated well by both infants due to its palatability and the twins' parents and carers found the formula easy to use.

Baby L saw a complete resolution in her diarrhoea, bloody stools, and abdominal distention ten days after starting on **Neocate Syneo**. Although baby L's

dermatitis improved, mild dermatitis on her face persisted and it was thought that this may not be a solely CMA related symptom. Baby M had complete resolution of her diarrhoea, abdominal distension, erythema, and irritability five days after commencing **Neocate Syneo**.

At their second and third consultations, baby L was at risk of malnutrition and short stature but was in the process of catch-up growth and baby M had age-appropriate weight and height, and a weight appropriate for her height.

Now, at 6 months of age, the twins have not yet started complementary feeding and neither infant has developed tolerance to cow's milk.

DISCUSSION

The switch to Neocate Syneo resulted in peace of mind and confidence for both baby L and M's parents and healthcare team. Given that both twins were experiencing symptoms of CMA, the symptom relief that Neocate Syneo caused had a large positive impact on their family environment as well as their finances.

The benefits of synbiotics are broadly supported by the research to date, including clinical trials, with meta-analyses and systematic reviews. This case study illustrates safe use of amino acid formulas with synbiotics in these premature babies and effective nutritional recovery. The quick resolution of CMA symptoms in both baby L and M may have been due to the synbiotics included in Neocate Syneo. The synbiotics potentially optimised the twins' immune systems; neither had an infection or needed antibiotics after starting on Neocate Syneo.

This case study illustrates safe use of amino acid formulas with synbiotics in these premature babies and effective nutritional recovery.

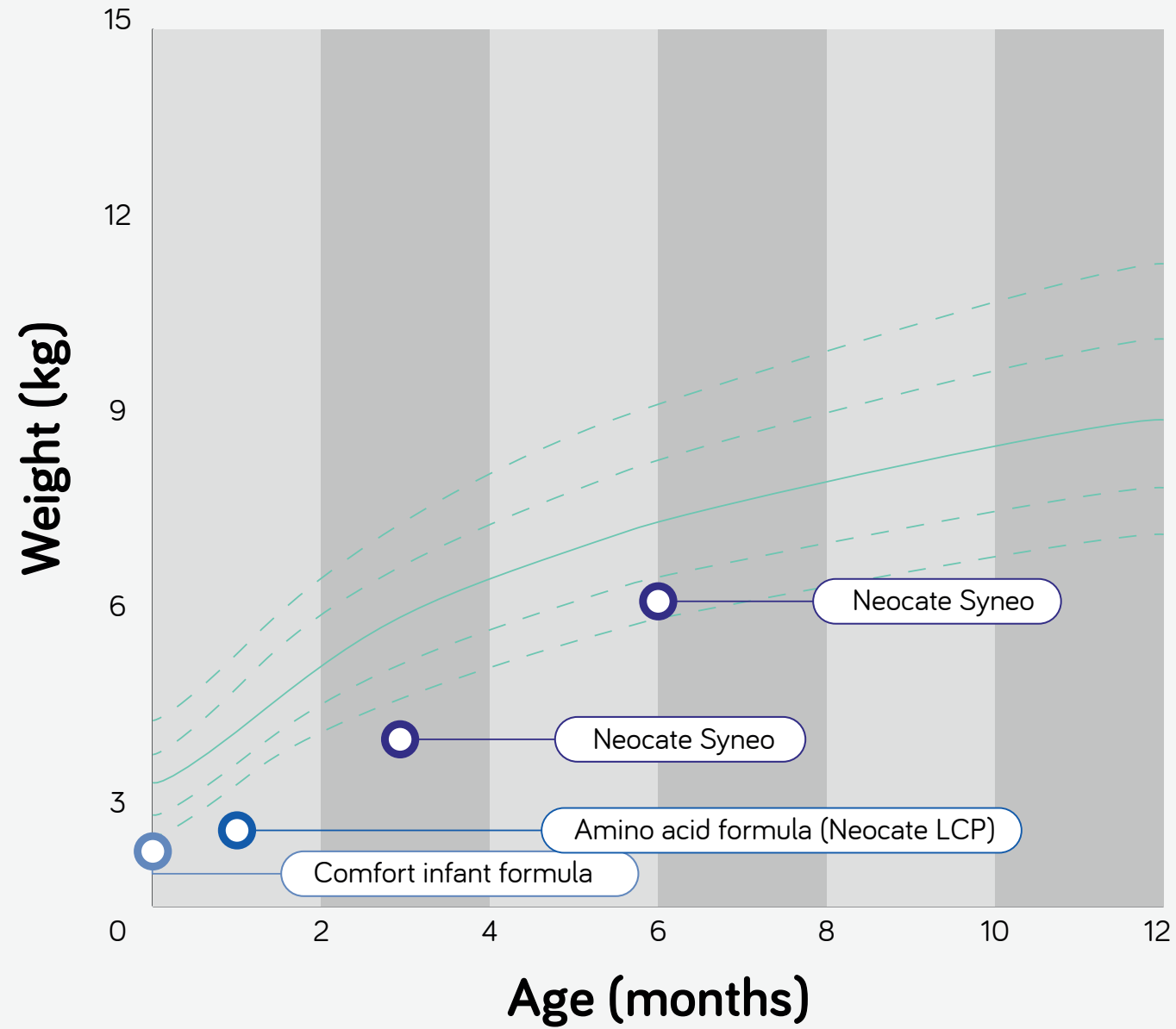
The synbiotics potentially optimised the twins' immune systems; neither had an infection or needed antibiotics after starting on Neocate Syneo.

CONCLUSION

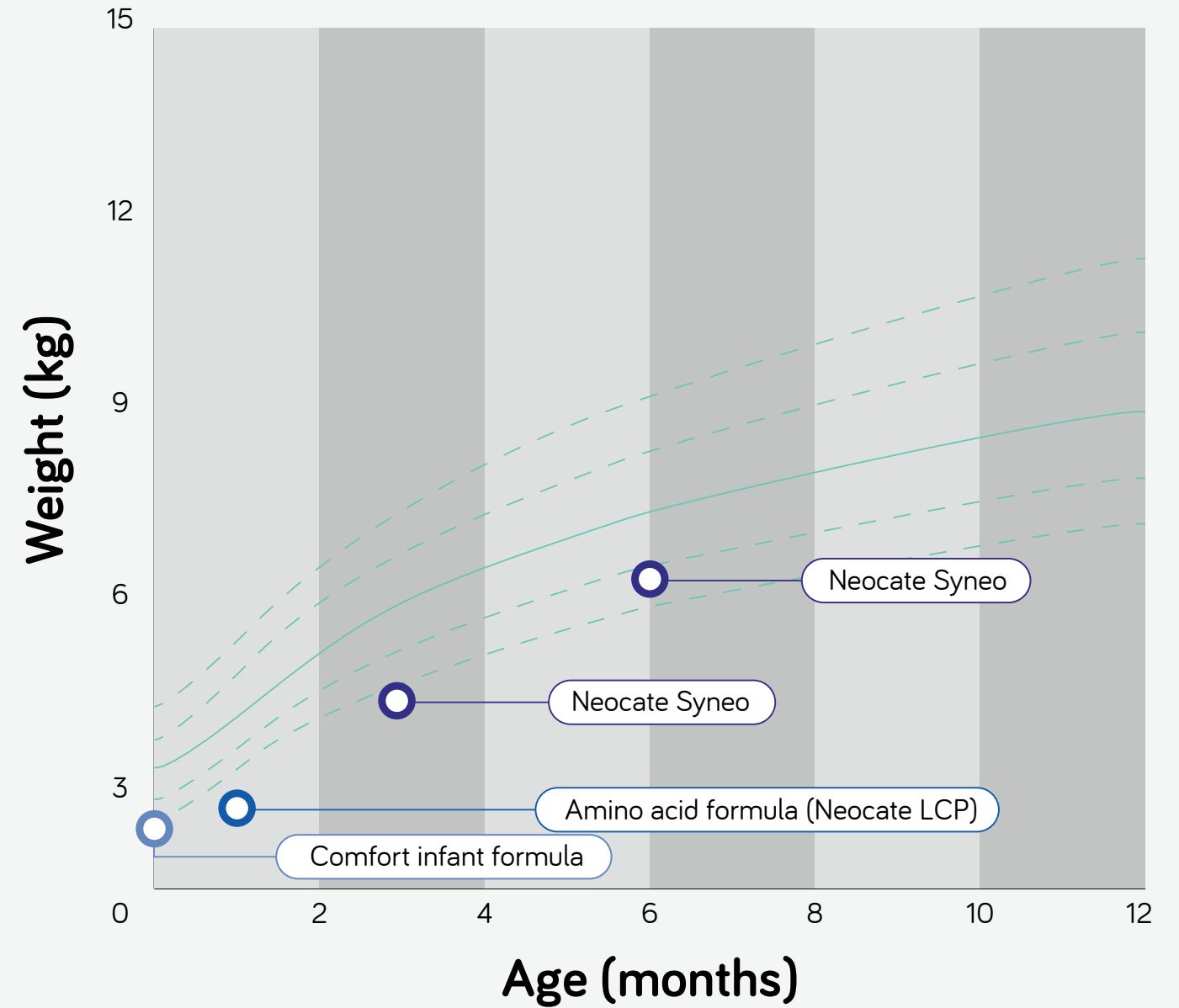
Baby L and M both tolerated Neocate Syneo well, had catch-up growth and quickly achieved the complete resolution of their GI symptoms ten and five days respectively after starting the formula. The switch had a positive impact on the twins' family environment and gave their parents and healthcare team peace of mind.

Case study continues on the next page.

GROWTH CHART: BABY L



GROWTH CHART: BABY M



Whilst the probiotic in Syneo, *Bifidobacterium breve* M-16V has been shown to be used safely in premature infants¹, it is well known that this group of infants may be immunocompromised. Therefore, Nutricia has taken a cautious approach to not recommend Neocate Syneo for this group of vulnerable infants before they reach term age (corrected age). Nutricia recommends Neocate Syneo to be used once the infant has reached his/hers corrected age.

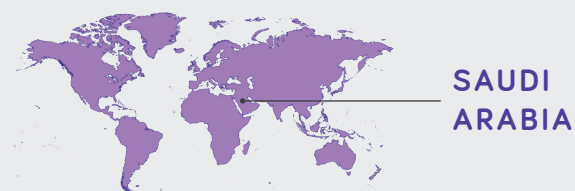
The choice of feed should always be determined by the HCP and is dependent on other factors such as the age, body weight and medical condition of the patient.

¹ Patole SK, Rao SC, Keil AD, Nathan EA, Doherty DA, Simmer KN. Benefits of *Bifidobacterium breve* M-16V Supplementation in Preterm Neonates - A Retrospective Cohort Study. Baud O, ed. PLoS One. 2016;11(3):e0150775. doi:10.1371/journal.pone.0150775

INFANT WITH PERSISTENT SKIN SYMPTOMS ON AN EHF

BABY N

Dr Najwa Alsawi Allergist/immunologist
Dr. Suliman Al Habib Group



PATIENT PROFILE

Full term infant with IgE-mediated cow's milk allergy (CMA), who previously received an extensively hydrolysed formula (eHF), saw a substantial improvement in eczema and was able to stop her steroid-based cream after eight weeks, following a switch to Neocate Syneo.

- IgE-mediated CMA
- Family history of asthma
- Dermatologic symptoms
- Prescribed emollient and steroid-based cream for eczema

BACKGROUND

Baby N was born at full term by vaginal delivery with no postnatal complications. Baby N has one older, healthy sibling and a family history of asthma (dad asthmatic). At four months old she was hospitalised for bronchiolitis. Baby N was exclusively breastfed until four months old before being weaned onto a standard infant formula at five months, and complementary foods were introduced at six months.

When baby N was weaned onto the standard infant formula at five months, she developed eczema and severe itching. At 11 months baby N was growing well within normal growth parameters. However, she was waking up every two hours, was irritated most of the time, trying to scratch her skin, needing to be constantly held and would often cry inconsolably.

MANAGEMENT

Baby N presented to the paediatrician with eczema at seven months and again at nine months; she was initially prescribed an emollient followed by a steroid-based cream, both times the eczema was initially improved with medication, but the eczema rashes re-appeared.

At 11 months baby N presented to the paediatric allergy clinic with a moist, erythematous rash on her cheeks, chest, back and the extensor surfaces of her arms. She underwent lab tests, and a diagnosis of CMA was made. Baby N showed a high Casein specific IgE level (80ku/l), her skin prick test gave a wheel diameter of 12mm.¹

Following her diagnosis of CMA baby N was started on an eHF. After a month of casein-based eHF her eczema was not improved, and baby N was switched onto Neocate Syneo, an amino-acid based formula with synbiotics. Neocate Syneo was used alongside an elimination diet of cow's milk free complementary foods including fruit, vegetables and grains. Within ten days of starting Neocate Syneo, baby N's mum saw an improvement in her eczema.

¹ For skin prick tests, an average wheel diameter above 3mm usually indicates an allergy. Kido, J., Hirata, M., Ueno, H., Nishi, N., Mochinaga, M., Ueno, Y., Yanai, M., John, M. and Matsumoto, T., 2016. Evaluation of the Skin-prick Test for Predicting the Outgrowth of Cow's Milk Allergy. *Allergy & Rhinology*, 7(3), pp.e139-e143. Van der Valk, J., Gerth van Wijk, R., Hoorn, E., Groenendijk, L., Groenendijk, I. and de Jong, N., 2015. Measurement and interpretation of skin prick test results. *Clinical and Translational Allergy*, 6(8).

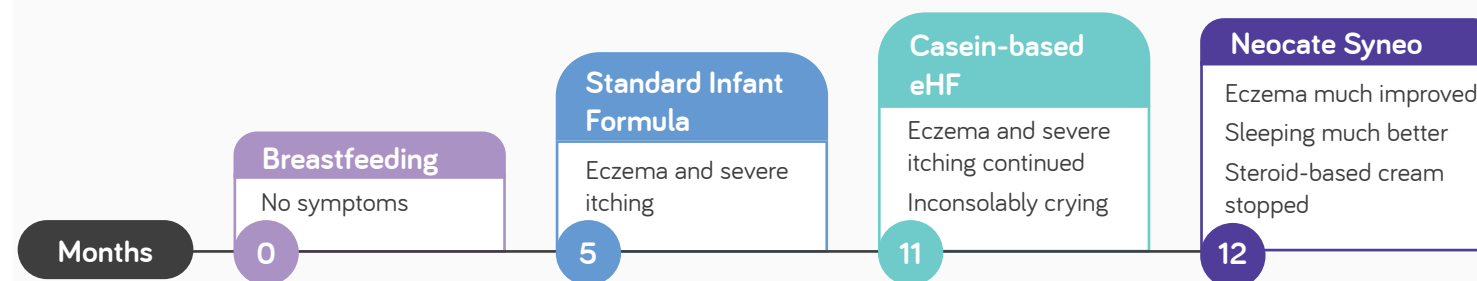
FOLLOW UP CARE

The aim of baby N's nutritional intervention was to avoid cow's milk protein and to increase her food tolerance, by improving her microbiota. **Neocate Syneo** was introduced at 12 months and was chosen because of the ability of synbiotics to stop or affect the progression of (other) allergies. Baby N didn't reject **Neocate Syneo**, and it was well tolerated.

Within four weeks of commencing **Neocate Syneo** baby N was sleeping much better; she was only waking up one to two times a night versus every two hours, as well as having longer daytime naps. Baby N's facial eczema was improved at four weeks. Although her body remained covered in eczema, it also showed signs of improvement.

After eight weeks, baby N's eczema was almost completely clear and her back, which was previously a mass of red eczema patches, was now smooth and clear. Baby N stopped using her steroid-based cream two months after the switch to **Neocate Syneo**. Now, at 15 months, a few patches of mild irritation persist on baby N's legs. She is sleeping through the night and is advised to continue feeding ad libitum with Neocate Syneo for 9-12 months.

TIMELINE



DISCUSSION

Neocate Syneo has been effective with most patients, as they don't experience severe abdominal gas, diarrhoea or constipation. Due to the existing dysbiosis (disruption in the gut microbiota), great improvements are seen in patients using Neocate Syneo. Providing infants with probiotics (included in the synbiotic blend) also decreases the probability of them developing an allergy in the future.

“
After eight weeks, Baby N's eczema was almost completely clear.

Baby N stopped using her steroid-based cream two months after the switch to **Neocate Syneo**.
”

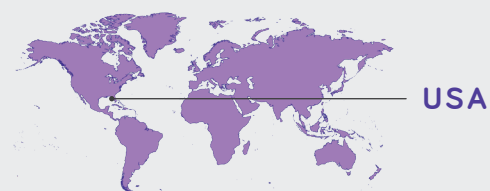
CONCLUSION

This CMA infant, who developed severe eczema after weaning onto a standard infant formula at six months, had almost complete resolution of her eczema eight weeks after switching to Neocate Syneo and stopped using her steroid-based cream. Baby N is now able to sleep through the night after previously waking every two hours. Switching Baby N to Neocate Syneo led to a satisfied healthcare team and satisfied parents.

INFANT WITH PERSISTENT VOMITING, MFA, AND FPIES

BABY O

Alicia D. Tenn Paediatric Nurse Practitioner
Paediatric Gastroenterology, Hepatology and Nutrition of Florida



PATIENT PROFILE

Infant born by caesarean section with multiple food allergies and food protein-induced enterocolitis syndrome (FPIES) trialled multiple formulas without success. Following the switch to Neocate Syneo Infant¹, the infant saw an improvement in gastrointestinal symptoms, growth and quality of life.

- FPIES
- Multiple food allergies (MFA)
- Prematurely born infant
- Faltering growth
- Gastrointestinal symptoms
- Dermatological symptoms
- Symptomatic on breastmilk, and many formulas including eHF and an AAF without synbiotics

BACKGROUND

Baby O was born at 37 weeks by caesarean section. Pregnancy had been complicated by maternal diabetes. At two weeks old, baby O presented with loose stools, significant vomiting and fits of screaming. At three weeks old, he developed bloody

diarrhoea and was referred to a gastroenterologist where he was diagnosed with milk soy protein intolerance (multiple food allergies). Baby O also presented with a rash (hive-like in appearance) and severe reflux.

MANAGEMENT

Baby O was trialled on multiple medications to manage his reflux; he started on ranitidine and esomeprazole, before moving to compounded omeprazole and then lansoprazole. To manage his vomiting, baby O's feeds were thickened and he was commenced on medication, including promotility agent erythromycin. However, these strategies were not sufficient to prevent baby O's vomiting and at one month old, baby O was hospitalised. On admission, he underwent a barium swallow test (upper gastrointestinal imaging test) which ruled out malrotation (twisted bowel).

In the first few months of life, baby O struggled to gain weight given his intolerances and frequent vomiting episodes. Baby O was breastfed and supplemented with formula, in line with maternal preference. Whilst baby O was breastfed his mother followed a restrictive elimination diet, excluding milk, soy and a number of other foods. Breastfeeding was trialled in combination with a number of formulas including a low-lactose formula, a partially hydrolysed low-lactose formula, an extensively hydrolysed formula (eHF) and a standard amino acid formula (AAF). Baby O didn't tolerate these formulas and they did not relieve his symptoms; they caused him pain which led to fits of inconsolable screaming.

¹ Neocate Syneo Infant is the USA formulation equivalent to Neocate Syneo in EU/Rest of world

FOLLOW UP CARE

At five and a half months old, baby O was started on an AAF with synbiotics, **Neocate Syneo** which he tolerated well and by six months old baby O was fully transitioned onto this new formula. Following the switch to **Neocate Syneo**, baby O's diarrhoea completely resolved and the frequency of his vomiting episodes decreased, both of which allowed baby O to grow adequately. Baby O's pain induced inconsolable screaming also significantly improved, positively impacting the quality of life of both baby O and his parents.

However, his reflux persisted and he continued to have a recurrent rash. Baby O's mother was concerned that despite following her strict elimination diet baby O was reacting to allergens in her breastmilk; she made the decision to cease breastfeeding and baby O was exclusively formula fed with **Neocate Syneo**.

When baby O began to introduce solids at around four months old, some of his allergy symptoms returned. He began presenting with one or a combination of bloody diarrhoea, delayed projectile vomiting and rashes, and was diagnosed with FPIES. As a result, solids were stopped and **Neocate Syneo** returned to being baby O's sole source of nutrition. He was seen by immunology, who requested that baby O was assessed by the genetics team before re-introducing solids, as there was a concern that baby O had systemic mastocytosis (accumulation of excess mast cells in body tissues).

In order to maintain baby O's growth, given that he couldn't tolerate large feeding volumes or solids, his feed was concentrated (from the standard 20kcal/fl oz (0.67 kcal/ml) to 24kcal/fl oz (0.80 kcal/ml), then to 27kcal/fl oz (0.90 kcal/ml) at nine months). The concentrated and thickened feeds in addition to medication helped to manage baby O's persistent reflux. By the age of two, baby O was able to tolerate some solids.

“
Baby O's diarrhoea completely resolved and the frequency of his vomiting episodes decreased, both of which allowed baby O to grow adequately.”

CONCLUSION

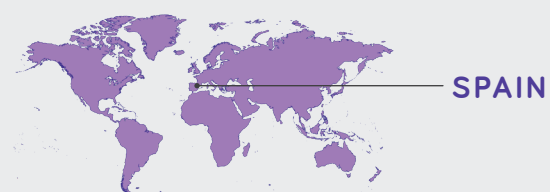
This case study focuses on an infant with medical issues including multiple food allergies, gastroesophageal reflux, FPIES, and feeding intolerance. Baby O trialled a number of different formulas without success before Neocate Syneo was introduced and best tolerated. The introduction of Neocate Syneo with pre- and probiotics had a positive effect on baby O's gastrointestinal symptoms, resolving his diarrhoea and lessening his vomiting, both of which allowed baby O to gain weight appropriately. The switch to Neocate Syneo also positively impacted baby O and his parents' quality of life by improving his pain behaviour.

“
Baby O trialled a number of different formulas without success before Neocate Syneo was introduced and best tolerated.”

INFANT BORN PREMATURELY WITH FALTERING GROWTH AND FOOD REFUSAL

BABY P

Gemma Castillejo Paediatric Gastroenterologist
Sant Joan de Reus University Hospital



PATIENT PROFILE

A baby born prematurely with non-IgE mediated cow's milk allergy (CMA) becomes asymptomatic and has quick catch-up growth using Neocate Syneo as the sole source of nutrition, despite historic use of extensively hydrolysed formula (eHF).

- Non-IgE mediated CMA
- Prematurely born infant
- Family history of asthma and penicillin allergy
- Infant antibiotic use
- Dermatological symptoms
- Gastrointestinal symptoms
- Feeding difficulties
- Symptomatic on an eHF

BACKGROUND

Baby P was born by vaginal delivery at 35+2 gestational weeks. Mum had no problems or illnesses during pregnancy and there were no specific risk factors for preterm delivery. There was a family history of asthma and penicillin allergy. Baby P showed respiratory distress and was admitted to

the neonatal intensive care unit (NICU) for 12 days before being discharged with no health problems. In the NICU, baby P received two days of supplementary oxygen, five days of intravenous antibiotics and five days of preterm formula via a nasogastric tube before moving to oral feeding.

MANAGEMENT

At 21 days of life baby P presented to the emergency room after a 48-hour history of diarrhoea, food refusal and weight loss. Baby P had metabolic acidosis. Apart from dry skin and his eyes looking sunken, he appeared well and had no fever or other symptoms. The parents reported that colic started in baby P after discharge from the NICU. Baby P had several episodes of vomiting and watery diarrhoea, with no blood or mucus. Till then, baby P was passing one formed stool a day. His diarrhoea persisted and there was a suspicion that he was developing an enteropathy due to CMA. Tests were run to rule out infections and IgE-mediated CMA. Stool viral antigens, stool culture, skin-prick test and serum-specific IgE testing for cow's milk were all negative.

Non-IgE mediated CMA was suspected. Baby P switched from a comfort formula, to an eHF, Pepti, with mild improvement.

One week later baby P presented again to the emergency room as he was uncomfortable during meals with crying, fussiness and colic after eating. Since discharge, he had an irritant diaper dermatitis and mum had observed streaks of blood in some of his semi-liquid stools. Baby P looked malnourished, with abdominal distention and increased peristalsis. The eHF was considered to be unsuccessful and baby P was switched to Neocate Syneo, an amino acid formula (AAF) with synbiotics. The target feeding volumes were never achieved, with the exception of Neocate Syneo (feeding regimen table on next page).

FOLLOW UP CARE

Before **Neocate Syneo** was commenced, baby P was not meeting his nutritional goals due his lack of growth. Baby P's failure to thrive had the potential to compromise his future health, especially given that he was a born prematurely. Baby P's short-term nutritional aim was to recover his weight and nutritional status and long-term was to maintain his weight and nutritional status.

On baby P's first admission to the emergency room, his weight (2.82kg) was lower than his birth weight, mainly due to faltering growth. Between the first and second emergency room visits, baby P's weight only increased by 80g. Once he switched from the eHF to the AAF **Neocate Syneo**, he rapidly recovered his growth curve (growth chart on next page).

Baby P was prescribed, and took, 90ml **Neocate Syneo** every three hours. Baby P accepted **Neocate Syneo** quite well and after five days, certain symptoms, including abdominal pain and flatulence, had lessened. Baby P's stools remained liquid but no

longer contained blood. After 12 days, baby P had no abdominal pain, scarce flatulence, was passing one normal stool per day and had improved colic and diaper dermatitis. Abdominal distention remained, along with a discrete increase in peristalsis. After one month of **Neocate Syneo** baby P was clinically asymptomatic, with the exception of occasional regurgitation.

Prior to baby P commencing **Neocate Syneo**, his family were concerned about his neurological development and very anxious about his worsening condition and increasing number of symptoms. Five days after the initiation of **Neocate Syneo** baby P's parents commented, "he is a totally different baby now, now we think we have got it".

Complementary foods, starting with fruit, were introduced at five months old without issue. Baby P passed a cow's milk (CM) challenge at 13 months, and CM was gradually introduced with no issues, starting with plain yoghurt.

DISCUSSION

Many studies have shown that infants with CMA may have dysbiosis (an imbalance of their gut microbiota). In the short-term, dysbiosis can cause infants to have abdominal fussiness i.e., gas, straining, diarrhoea, bloating and colic, and may be responsible for the appearance or exacerbation of atopic dermatitis. Maintaining eubiosis (a balanced microbiota) can prevent complications such as acute gastroenteritis which would eventually require the use of antibiotics, causing more dysbiosis.

If dysbiosis is already present, synbiotics can help to recover the desired balance. Baby P's clinical picture on admission to the emergency room as suggestive of acute gastroenteritis. However, non-IgE

“
After one month of Neocate Syneo baby P was clinically asymptomatic, with the exception of occasional regurgitation

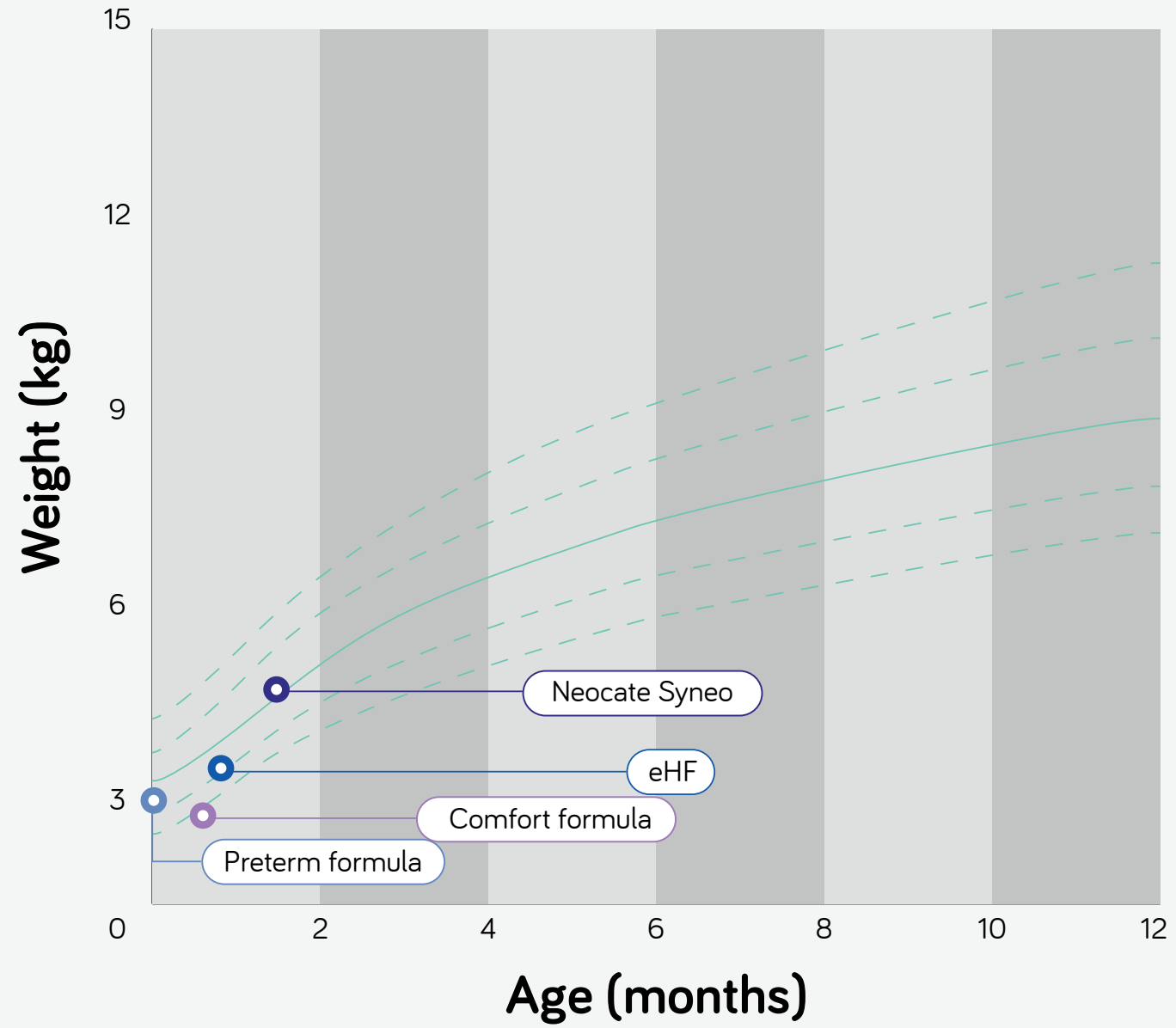
CMA was diagnosed as baby P's diarrhoea persisted accompanied by additional symptoms. Given that baby P was a particularly vulnerable patient (born prematurely), the amino acid formula could have been initiated first, in place of the eHF. Neocate Syneo was chosen due to the potential positive impact of synbiotics, especially given baby P's likely dysbiosis as a result of prematurity and CMA.

CONCLUSION

In this non-IgE mediated CMA infant, a switch from an eHF to an amino acid formula with synbiotics, Neocate Syneo, resulted in baby P recovering his growth curve. Initiation of Neocate Syneo also provided rapid symptom improvement, with baby P becoming asymptomatic in one month.

Case study continues on the next page.

GROWTH CHART



“
Once he switched from the eHF to the AAF **Neocate Syneo**, he rapidly recovered his growth curve.”

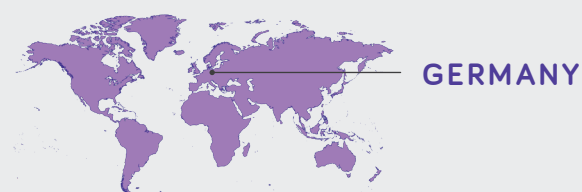
FEEDING REGIMEN

AGE	FEED (PRESCRIBED INFANT FORMULA)	AMOUNT OF FEEDING TIMES/ DAY	TARGET VOLUME/ DAY	TARGET VOLUME ACHIEVED?
21 days	Comfort formula	8	480ml	No
27 days	Extensively hydrolysed whey formula	6	540ml	No
45 days	Neocate syneo	6	540ml	Yes

INFANT WITH MULTIPLE GI AND DERMATOLOGICAL SYMPTOMS AND LONG PERIODS OF CRYING

BABY Q

Dominik Fürsich Paediatrician
Paediatric and Adolescent Practice Altdorf



PATIENT PROFILE

IgE-mediated cow's milk allergic infant, with a family history of hay fever and atopic dermatitis, experienced symptom resolution in three days following a switch from a partially hydrolysed formula (pHF) to a synbiotic containing amino acid formula, Neocate Syneo.

- IgE-mediated CMA
- Family history of hay fever and atopic dermatitis
- Gastrointestinal symptoms
- Dermatological symptoms

BACKGROUND

Baby Q was born at full term weighing 2.52kg. There is a family history of hay fever and atopic dermatitis, and baby Q has two siblings and a pet dog. At birth baby Q was commenced on a standard cow's milk formula. Baby Q had both gastrointestinal and dermatological symptoms of watery stools, facial eczema, colic, back arching and was permanently inconsolable. At four weeks old, he presented to the

emergency room due to colic and inconsolability. He was seen again at his six-week routine check-up; baby Q continued to experience symptoms and his mother reported he was unable to sleep and had excessive gas. Baby Q scored a 47 using the SCORAD (SCORing Atopic Dermatitis) tool¹, indicating severe atopic dermatitis.

MANAGEMENT

After presenting at the emergency room at four weeks old, baby Q was switched from his standard cow's milk formula to a pHF on account of his family history of hay fever and atopic dermatitis. Following this change, his stools shifted from watery to soft stools. No cause was found for baby Q's symptoms of colic and inconsolability and these symptoms persisted. Baby Q was first seen in the paediatric medical practice for his routine six-week check-up. At this check-up, given his background of diarrhoea,

inconsolability and eczema, he was switched from a pHF to Neocate Syneo. Three days after the switch his eczema, colic, diarrhoea and inconsolability almost completely subsided. Ten days after commencing Neocate Syneo, baby Q underwent a provocation test with pHF and his diarrhoea and colic returned. Following his positive provocation test, a diagnosis of IgE-mediated cow's milk allergy (CMA) was made and baby Q returned to Neocate Syneo.

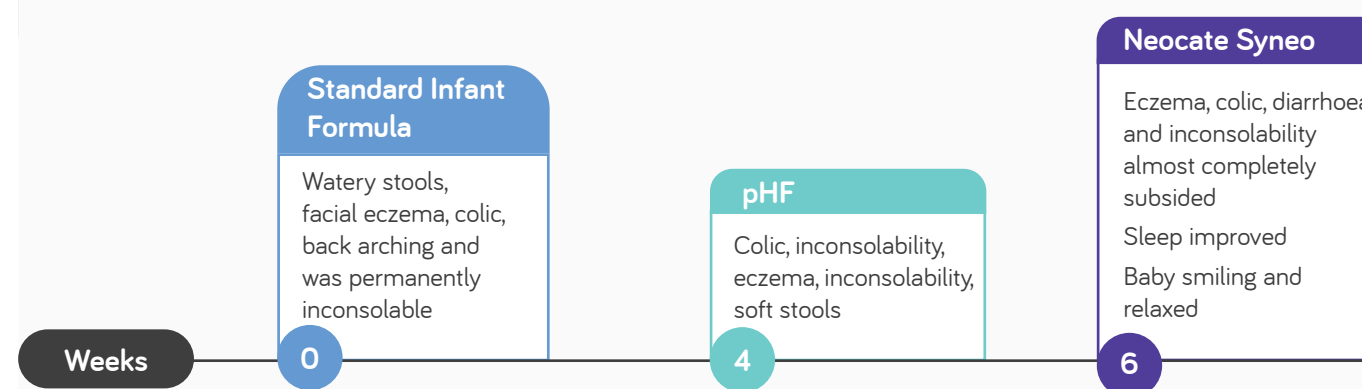
¹ Oranje A. Practical issues on interpretation of scoring atopic dermatitis: SCORAD Index, objective SCORAD, patient-oriented SCORAD and Three-Item Severity score. *Current problems in dermatology*. 2011; 41:149-155.

FOLLOW UP CARE

The aim of baby Q's nutritional intervention was to stop his colic, diarrhoea and to improve his skin status. At six weeks, baby Q commenced **Neocate Syneo** and after one day he slept for several hours without waking for the first time in his life. After three days, baby Q's stools were creamy, he had no excessive gas, and his eczema was almost resolved.

After three days of **Neocate Syneo**, baby Q was smiling and relaxed and his long periods of crying had almost completely stopped. Baby Q continued to have **Neocate Syneo** until he was one year old. At present, baby Q is a toddler and is consuming cow's milk and cow's milk products with no issues.

TIMELINE



DISCUSSION

Having a healthy gut microbiota is particularly important in atopic infants. Given the synbiotic blend included in Neocate Syneo and the positive impact that this has on the gut microbiota, this was the formula of choice for baby Q.

Baby Q's family had been burdened with his crying since his first week of life. Following the switch to Neocate Syneo, baby Q was no longer permanently inconsolable.

“After three days of **Neocate Syneo**, baby Q was smiling and relaxed and his long periods of crying had almost completely stopped. **Neocate Syneo** resulted in rapid symptom improvement, with symptoms almost completely subsiding after three days of **Neocate Syneo**.”

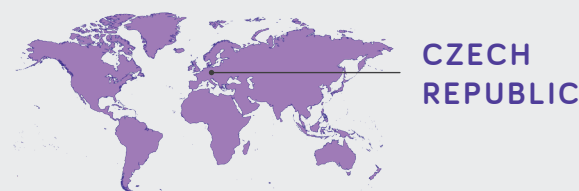
CONCLUSION

In this IgE-mediated CMA infant, who previously suffered with multiple gastrointestinal and dermatological symptoms, switching from a pHF to Neocate Syneo resulted in rapid symptom improvement, with symptoms almost completely subsiding after three days of Neocate Syneo.

INFANT WITH ECZEMA, VOMITING AND CONSTIPATION

BABY R

Simona Bělohávková Allergist/immunologist
Immuno-Flow Private Clinic Prague



PATIENT PROFILE

Full term infant born by caesarean section with both IgE and non-IgE mediated cow's milk allergy (CMA), saw a rapid and significant improvement in her gastrointestinal (GI) and dermatological symptoms following a switch from an extensively hydrolysed formula (eHF) to Neocate Syneo.

- IgE and non-IgE mediated CMA
- Born by caesarean section
- Family history of hay fever and eczema
- Dermatological symptoms
- Gastrointestinal symptoms
- Symptomatic on eHF

BACKGROUND

Baby R was born at full term by caesarean section, with no complications before or after the birth. Baby R has two siblings and a family history of hay fever and eczema. Baby R was breastfed for the first month of life before being transitioned onto a standard infant

formula. At one month old, after the introduction of the standard infant formula, baby R presented with eczema, colic, crying, vomiting, reflux, constipation and was inconsolable. At four months, baby R's general practitioner (GP) suspected cow's milk allergy.

MANAGEMENT

From one to four months old she continued to be fed with a standard infant formula. At four months old, complementary feeding was commenced and baby R's GP prescribed her an eHF, Pepti Syneo. This feed change resulted in a slight improvement to baby R's eczema and behaviour, but had no effect on her constipation. She was also prescribed antihistamines and local skin steroids, but her eczema remained very itchy.

Cow's milk allergy was suspected based on her clinical presentation; she displayed a combination of GI and dermatological symptoms when taking a standard infant formula, and these symptoms were slightly improved following the introduction of Pepti Syneo. Baby R was managed according to the Czech CMA diagnosis and therapy guidelines and she maintained a normal height and weight throughout.

Baby R first presented to the allergology clinic at seven months old. She was displaying persistent symptoms of CMA, namely atopic dermatitis, vomiting, reflux, constipation and crying. Baby R underwent multiple allergy tests. Her skin prick tests were negative for milk and positive with egg whites (3mm diameter). Baby R had positive specific IgE antibodies to whole cow's milk (0.66 kU/L), alpha-lactalbumin (1.44 kU/L), casein (0.57 kU/L) and egg white (2.2 kU/L). Due to the presence of immediate (vomiting and crying) and delayed symptoms (eczema and constipation), and a positive open challenge test with an extensively hydrolysed formula after 4 weeks with Neocate Syneo, baby R was diagnosed with both IgE and non-IgE mediated CMA.

FOLLOW UP CARE

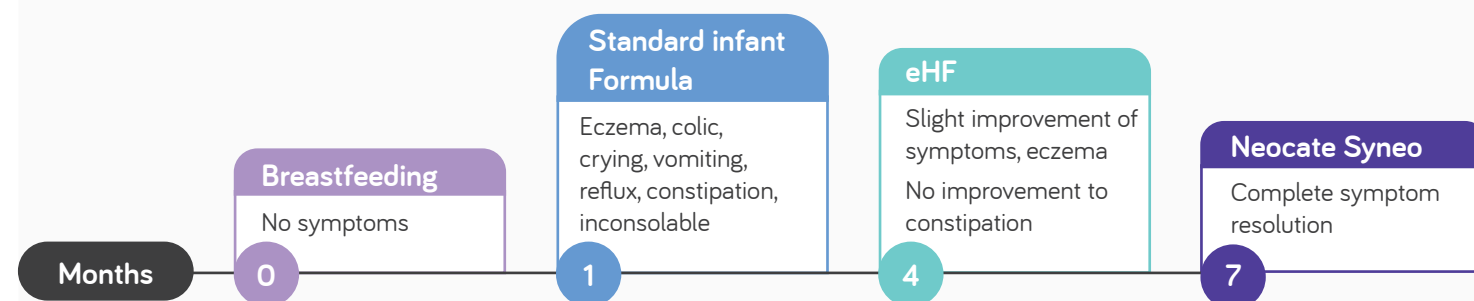
The aim of baby R's nutritional intervention was symptom improvement, particularly of her atopic eczema, vomiting and constipation. Following the failure of the eHF Pepti Syneo to effectively relieve all her symptoms, at seven months old baby R was switched onto an amino acid-based formula, **Neocate Syneo**. **Neocate Syneo** was chosen due to positive previous experiences using the product and given that baby R was displaying both dermatological and GI symptoms. **Neocate Syneo** was immediately well tolerated and baby R was quickly able to meet her feed target volume of 600ml/day. Within two weeks of the switch to **Neocate Syneo**, baby R saw a significant improvement in her gastrointestinal symptoms and after four weeks, her dermatological

symptoms were improved. On baby R's third visit to the allergology clinic, at 12 months old, her symptoms had completely resolved. Baby R was able to stop all her medications (antihistamines and local steroids).

Baby R's symptom resolution had a positive impact on her families' quality of life; her parents were very satisfied with the formula, baby R's compliance was very good and her crying was reduced.

Baby R was challenged at 13 months old, but she hadn't developed tolerance. Baby R is planned to continue with **Neocate Syneo** until 15-17 months old, when another tolerance challenge with an eHF or standard infant formula is planned.

TIMELINE



DISCUSSION

In infants with CMA, nutrition is the most important therapeutic intervention. Neocate Syneo could be important for children with persistent CMA where extensively hydrolysed formula fails; it was potentially the synbiotics in Neocate Syneo which impacted baby R's resolution of constipation (normal stool frequency) and the improvement of her atopic eczema.

“
On baby R's third visit to the allergology clinic, at 12 months old, her symptoms had completely resolved. Baby R was able to stop all her medications (antihistamines and local steroids).
Neocate Syneo was very well tolerated and the switch left baby R's parents and healthcare team very satisfied.”

CONCLUSION

Baby R experienced a complete resolution of her dermatological and GI symptoms after Neocate Syneo was commenced. Neocate Syneo was very well tolerated and the switch left baby R's parents and healthcare team very satisfied.

At Nutricia, we believe in the power of nutrition to make a positive and measurable difference to health. Every day we are inspired by our purpose: to pioneer nutritional discoveries that help people of every age live longer, healthier lives.

For more information about Nutricia and Pepti Syneo and Neocate Syneo please visit:

Nutricia.com



Nutricia Specialised Nutrition
Taurusavenue 167, 2132 LS Hoofddorp
The Netherlands

